



CENTRO
DE PESQUISA E PÓS GRADUAÇÃO



**PUC
GOIÁS**

PÓS PUC



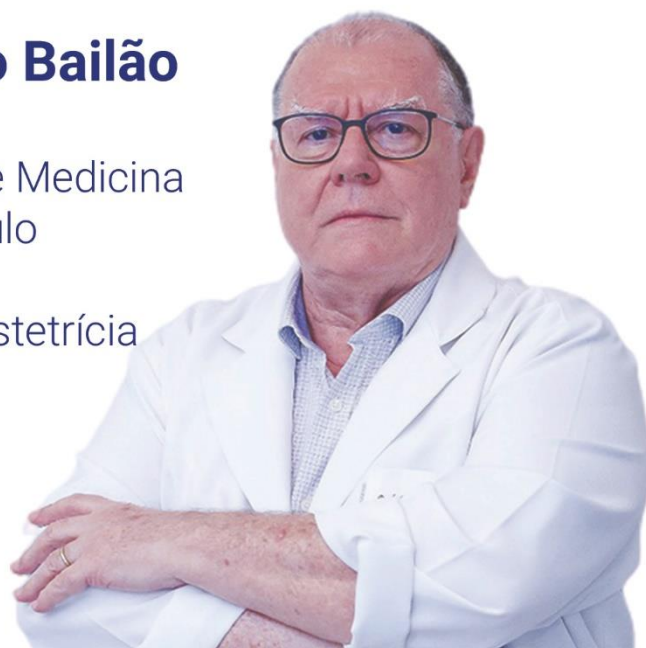ultraeduc
CURSOS DE ULTRASSONOGRAFIA

CURSO DE PÓS-GRADUAÇÃO LATO SENSU

**ULTRASSONOGRAFIA EM GINECOLOGIA,
OBSTETRÍCIA E MEDICINA INTERNA**

Coordenador: Prof. Dr. Luiz Antônio Bailão

- Médico, Mestre e Doutor pela Faculdade de Medicina de Ribeirão Preto – Universidade de São Paulo
- Título de Especialista em Ginecologia e Obstetrícia pela AMB/FEBRASGO
- Título de Especialista em Ultrassonografia Geral pela AMB/CBR



Reforçaremos os alicerces do conhecimento médico, trabalhando simultaneamente com os fundamentos (Embriologia, Anatomia, Fisiologia, Patologia e Fisiopatologia) e com a Semiologia Clínica aplicada à Ultrassonografia.

Mais de 20.000 imagens comentadas detalhadamente e exames práticos em inúmeros pacientes, supervisionados pelo Professor Bailão e equipe de profissionais maduros.

Os médicos inscritos no Curso de Pós-graduação participam de um grupo privado na internet para intercâmbio profissional. Já são 14 turmas de formandos. O Professor Bailão oferece assessoria permanente aos participantes, discutindo casos clínicos e ajudando a resolver casos difíceis, que fatalmente surgem em nosso dia a dia.

Juntem-se a nós, para mergulharmos a fundo na Ultrassonografia em áreas tão importantes da Medicina. O certificado é outorgado pela Pontifícia Universidade Católica de Goiás e registrado no Ministério da Educação e Cultura.

Apresentaremos, a seguir, o programa do próximo curso que ministraremos. Incluímos algumas imagens exemplares das várias disciplinas. Essas imagens são de propriedade intelectual do Prof. Bailão.

Autorizamos o uso das imagens em apresentações ou em publicações, desde que se faça a citação da autoria: Prof. Dr. Luiz Antônio Bailão.

CONTEÚDO PROGRAMÁTICO

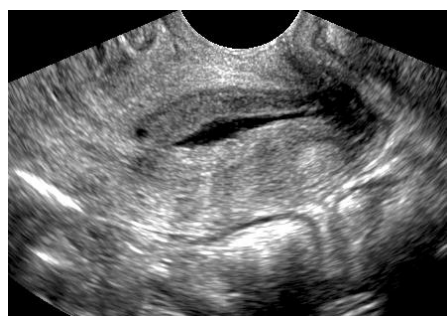CARGA HORÁRIA TOTAL: 480 HORAS
ATIVIDADES TEÓRICAS: 224 HORAS
ATIVIDADES PRÁTICAS: 160 HORAS
ESTUDO E PESQUISA BIBLIOGRÁFICA: 96 HORAS

MÊS 01. Disciplinas:

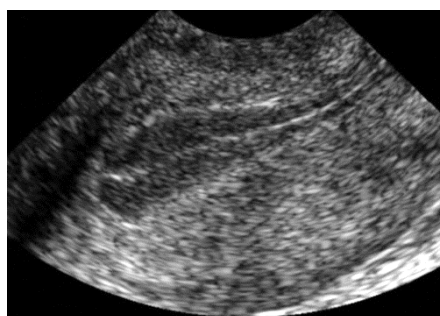Disciplina 1. Ultrassonografia: Princípios, Métodos e Aplicações.

Disciplina 2. Ultrassonografia em Ginecologia: Anatomia, Fisiologia e Biometria.

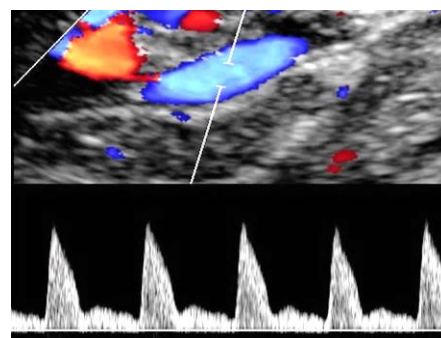
Alguns exemplos:



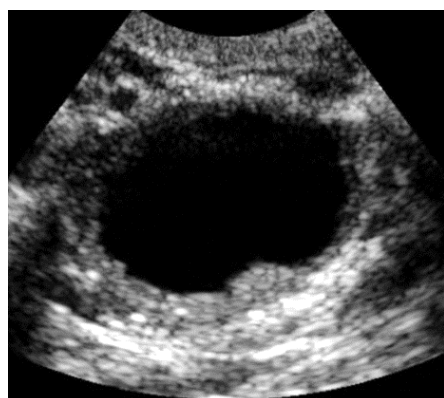
Colo e canal cervical



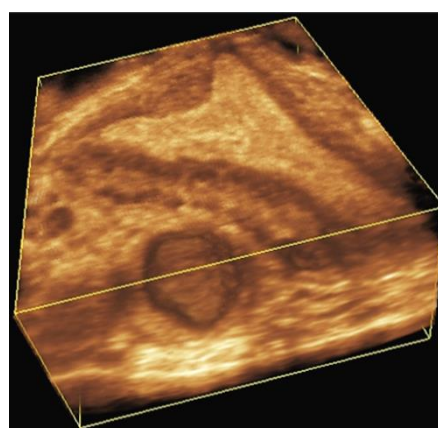
Endométrio proliferativo



Doppler da artéria uterina



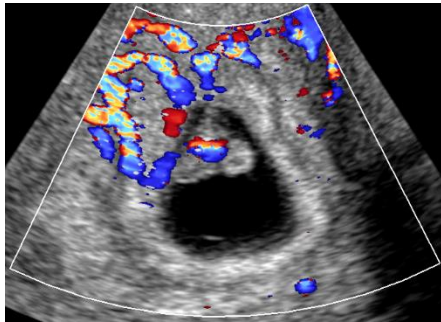
Folículo ovariano maduro



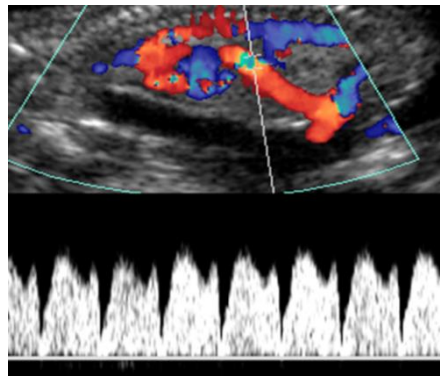
Anatomia tridimensional

Disciplina 3. Anatomia, Fisiologia e Biometria da Gravidez.

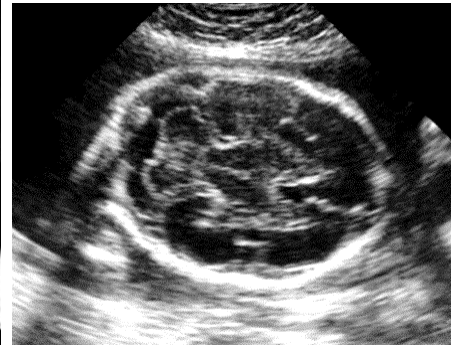
Alguns exemplos:



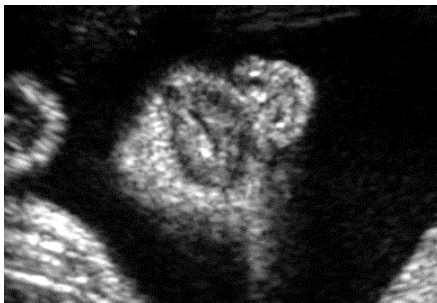Embrião



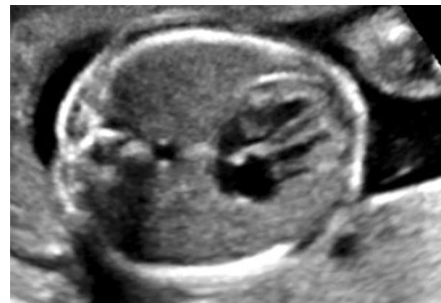Doppler do ducto venoso



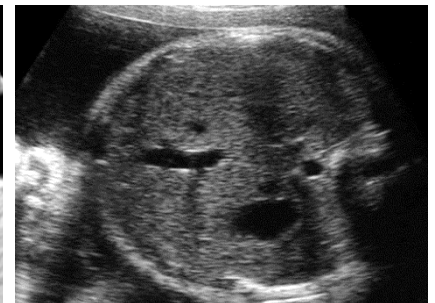Cerebelo



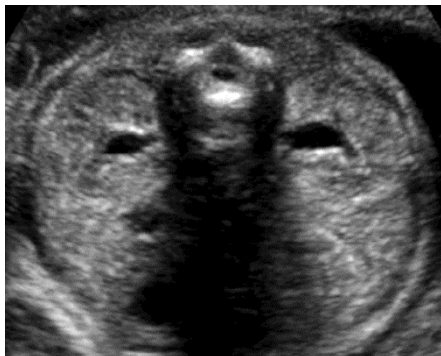Boca e nariz



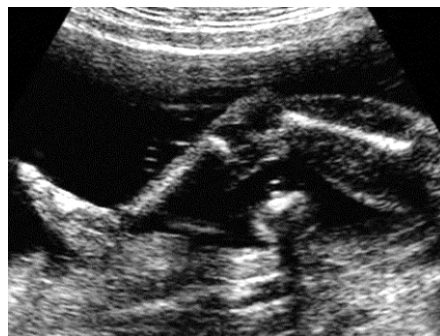Coração e pulmões



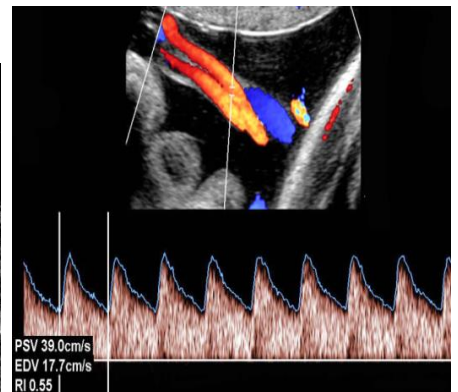
Fígado e estômago



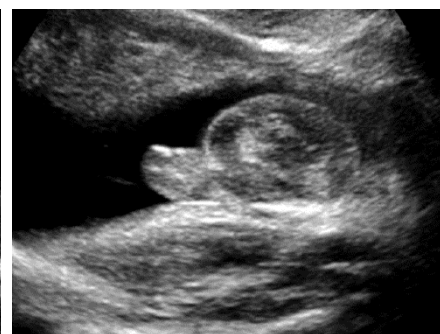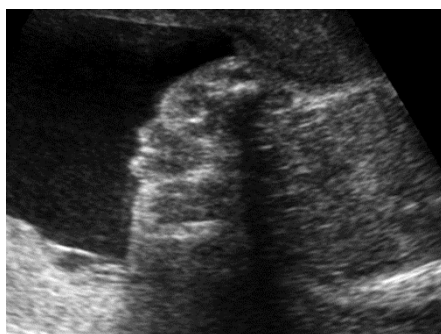Rins



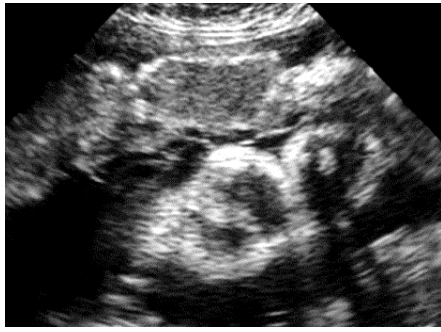Membro inferior



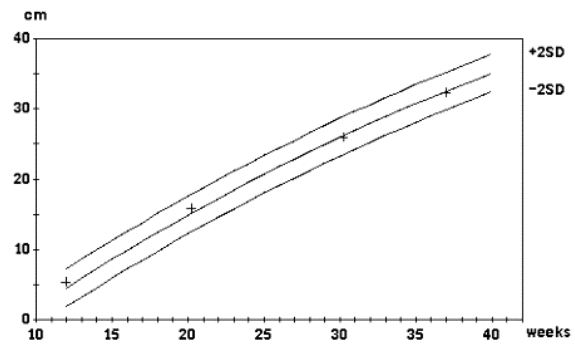
Doppler da artéria umbilical



Genitais



Placenta e líquido amniótico

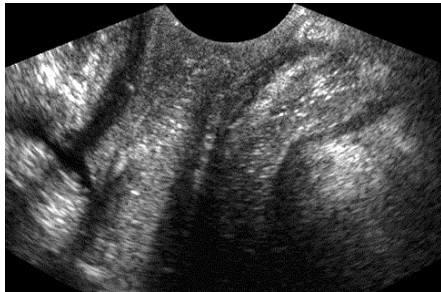


Crescimento fetal

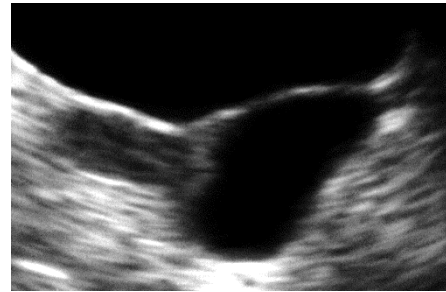Mês 02. Disciplinas:

Disciplina 1. Ultrassonografia da Vagina.

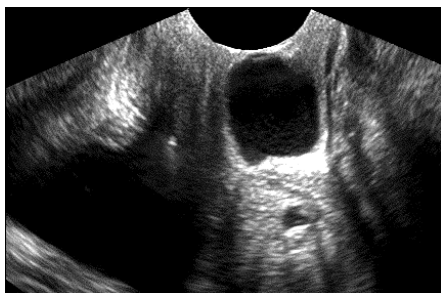Alguns exemplos:



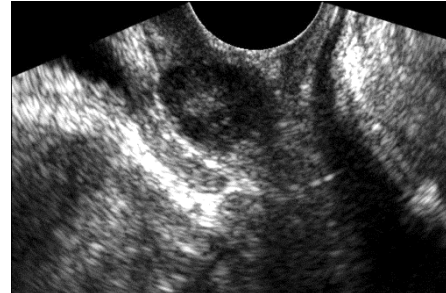Uretra, vagina e reto



Septo transverso: obstrução



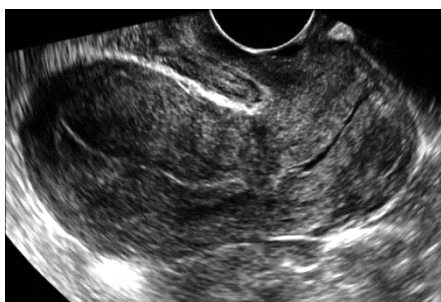Cisto em resíduo embrionário



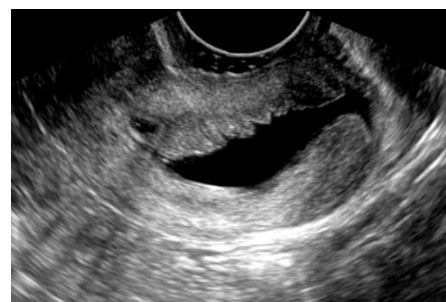Neoplasia

Disciplina 2. Ultrassonografia do Colo Uterino.

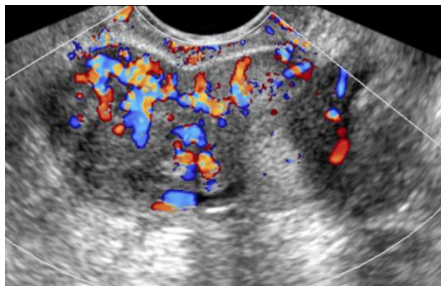
Alguns exemplos:



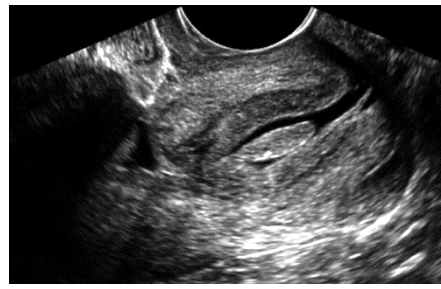
Útero: corpo e colo



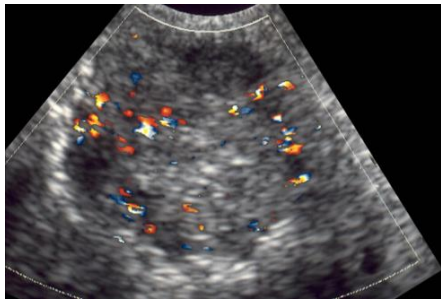
Colo: mucosa e muco abundante



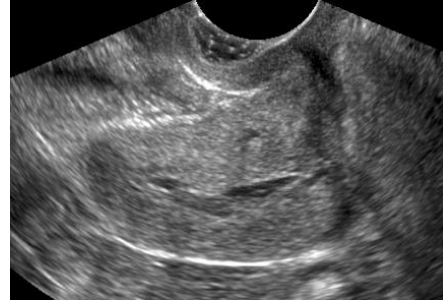Mioma paracervical



Pólipo endocervical



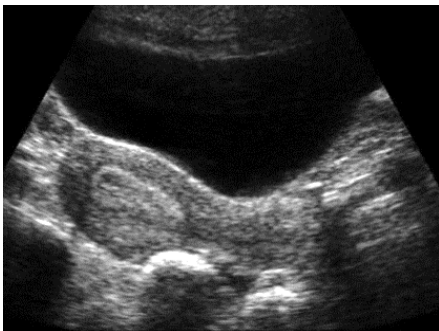
Carcinoma invasor



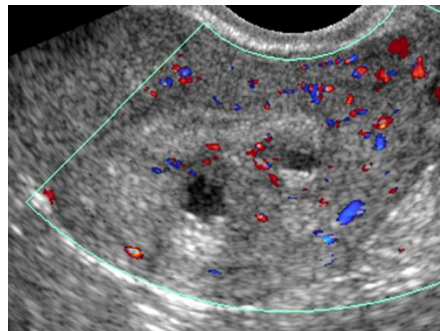
Histerectomia parcial: colo residual

Disciplina 3. Ultrassonografia do Miométrio.

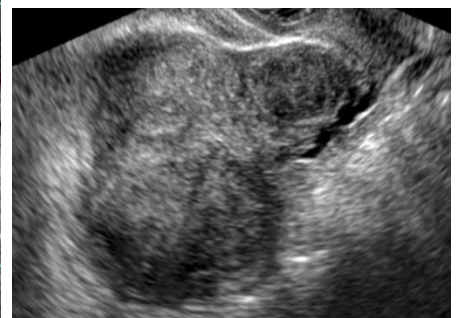
Alguns exemplos:



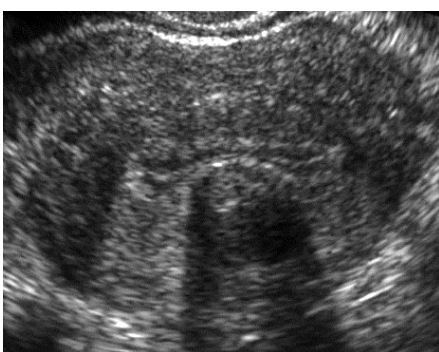Anatomia



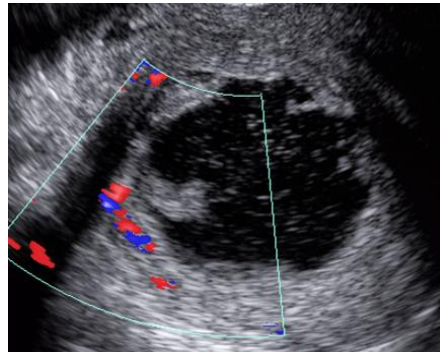
Adenomiose



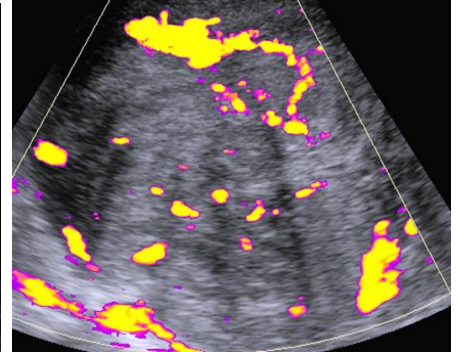
Mioma



Mioma submucoso

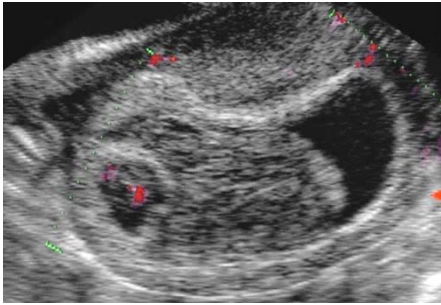


Mioma: degeneração cística

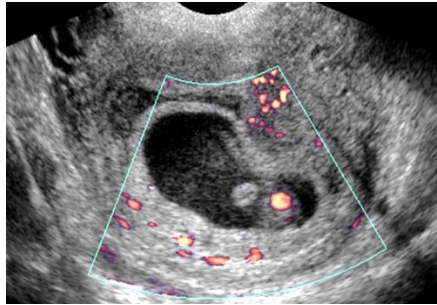


Sarcoma miometrial

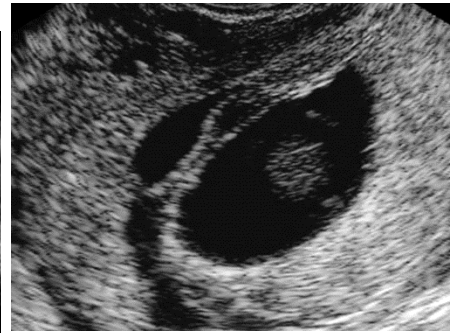
Disciplina 4. Abortamento.
Alguns exemplos:



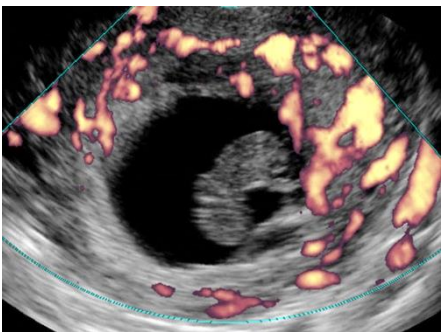
Sangramento: hematoma



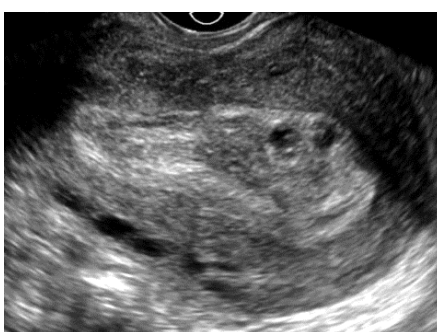Vesícula vitelina sólida



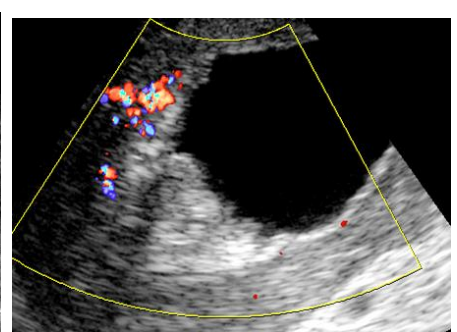
Abortamento inevitável



Óbito embrionário

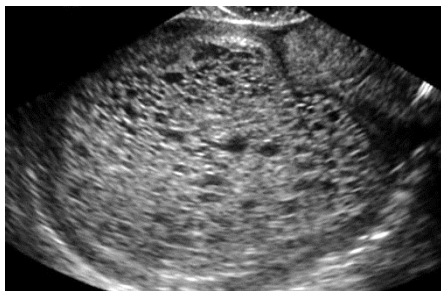

Aborto incompleto

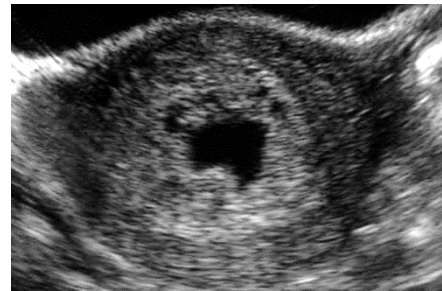


Ovo anembrionado

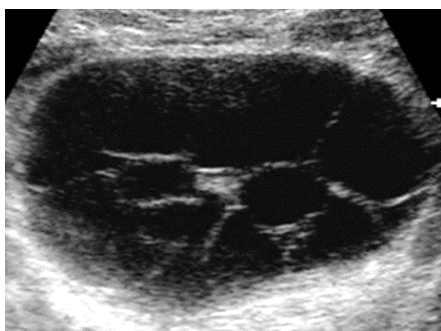
Disciplina 5. Doença Trofoblástica Gestacional
Alguns exemplos:



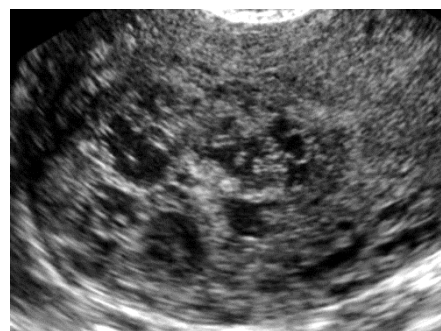Mola hidatiforme completa



Mola hidatiforme incompleta



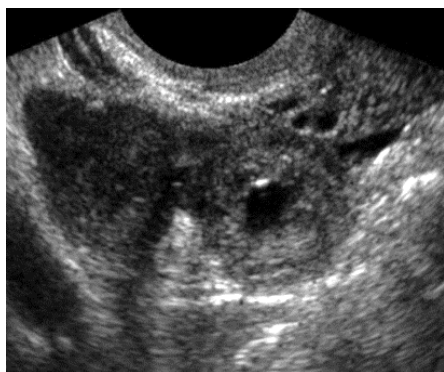Cistos deciduais



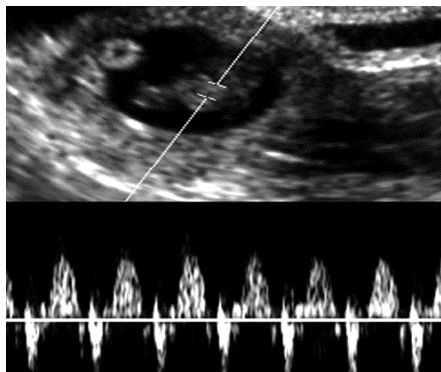
Mola invasora

Disciplina 6. Gravidez Ectópica

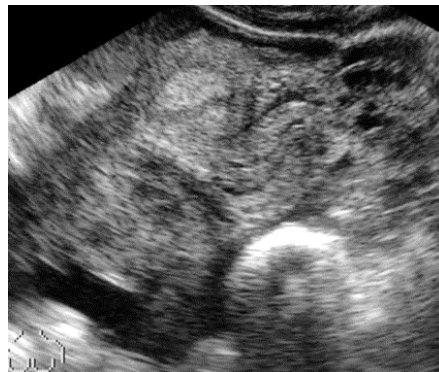Alguns exemplos:



Anel corial tubário



Ectópica: concepto vivo

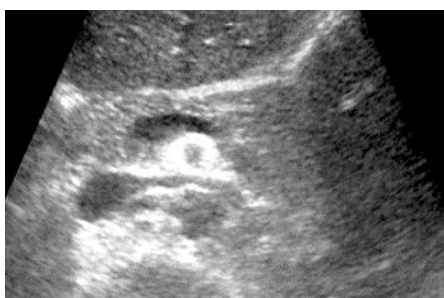

Ectópica rota

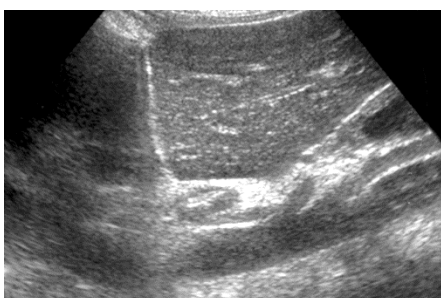
Mês 03. Disciplinas:

Disciplina 1. Anatomia Ecográfica do Abdome.

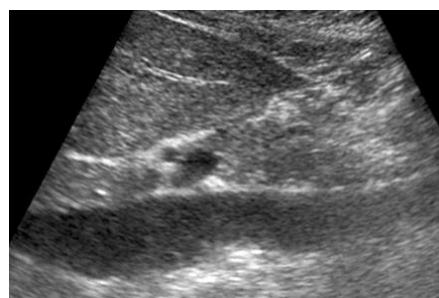
Alguns exemplos:



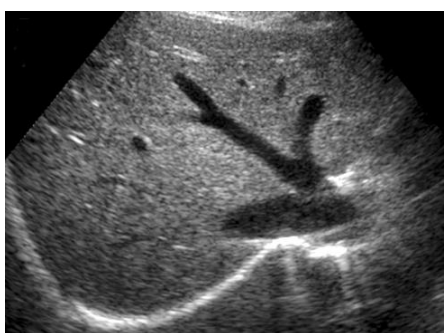
Pâncreas



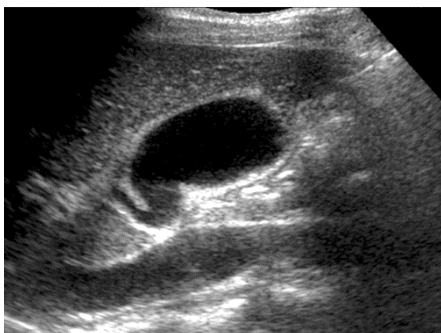
Artéria aorta



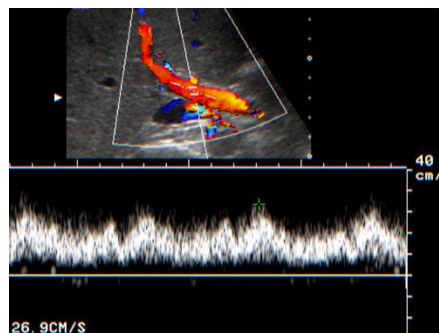
Veia cava inferior



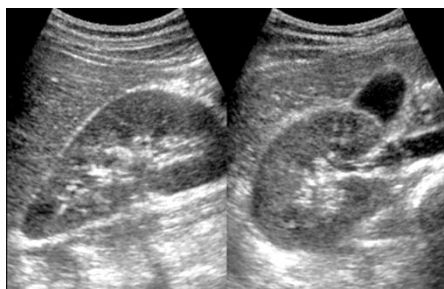
Fígado



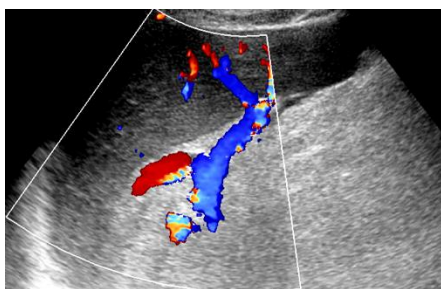
Vesícula biliar



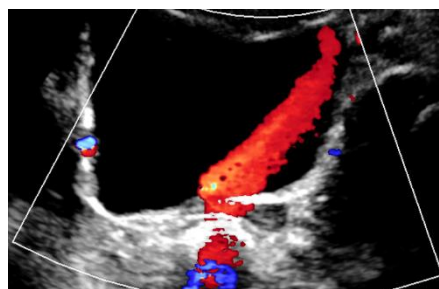
Veia porta



Rim



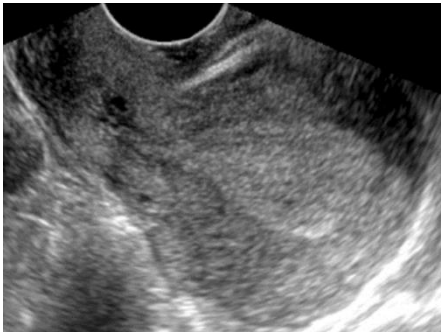
Baço



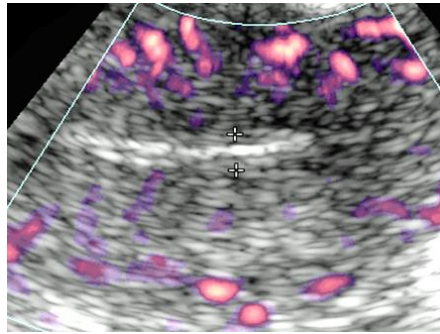
Bexiga: jato ureteral

Disciplina 2. Ultrassonografia do Endométrio.

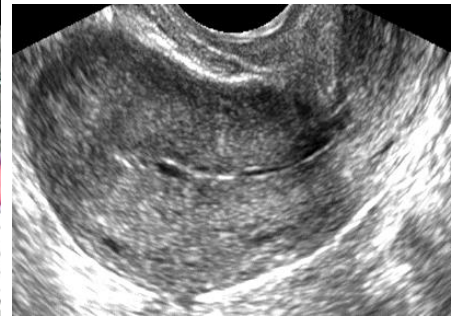
Alguns exemplos:



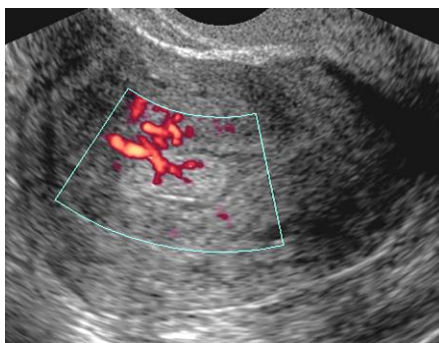
Endométrio secretor



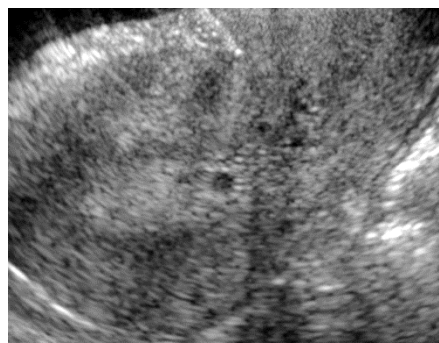
Endométrio mal desenvolvido



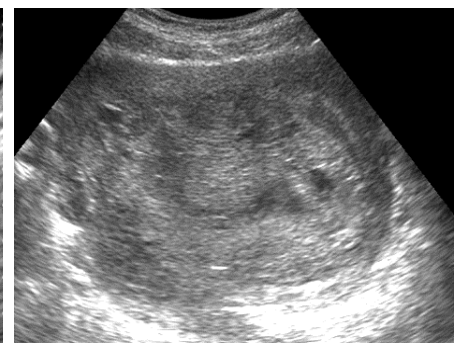Sinequia completa



Pólipo endometrial



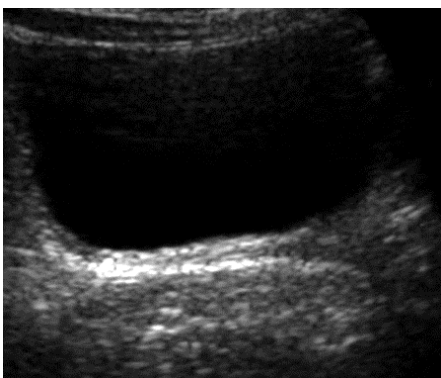
Hiperplasia endometrial



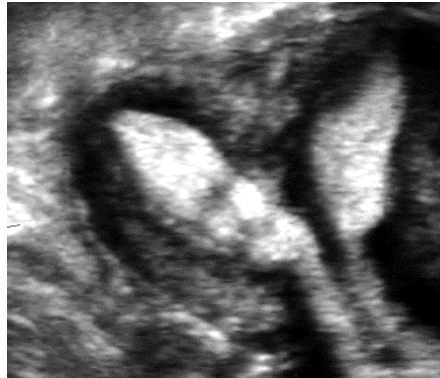Carcinoma endometrial

Disciplina 3. Malformações do Aparelho Genital Feminino.

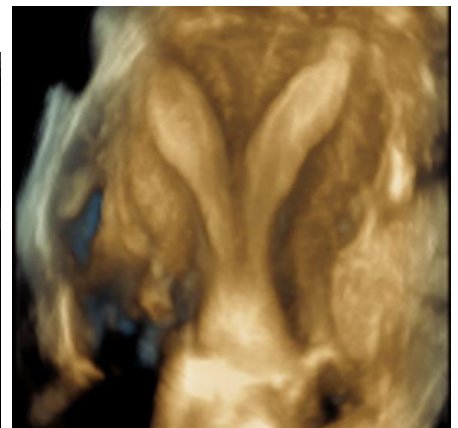
Alguns exemplos:



Síndrome de Rokitansky

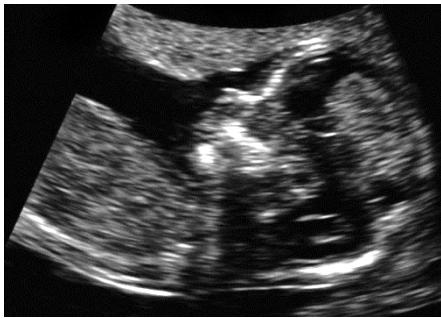

Útero bicorno bicolo

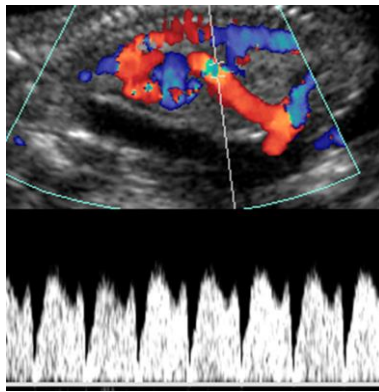


Útero septado

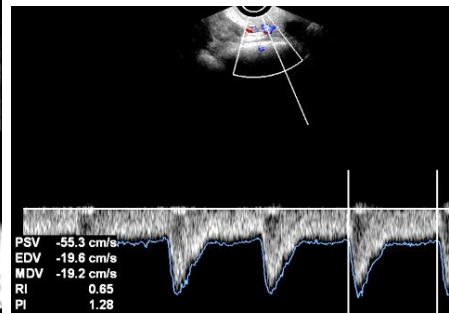
Disciplina 4. Ultrassonografia Morfológica do Primeiro Trimestre. Alguns exemplos:



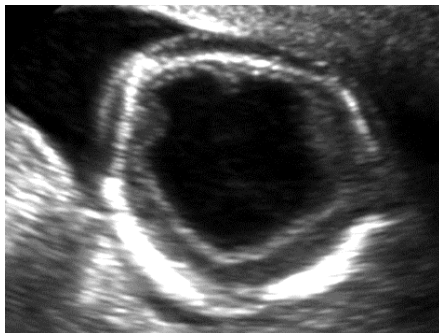
Face: marcadores



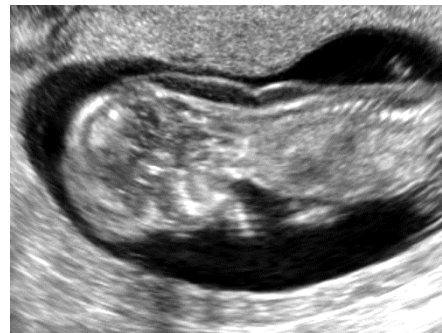Ducto venoso



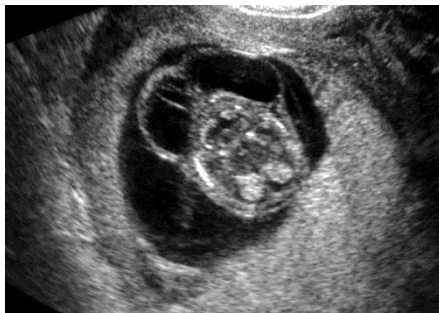Artéria uterina



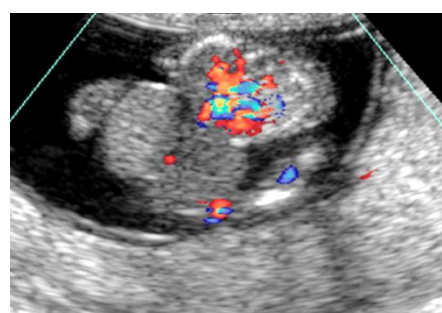
Holoprosencefalia



Translucência nugal



Higroma cístico



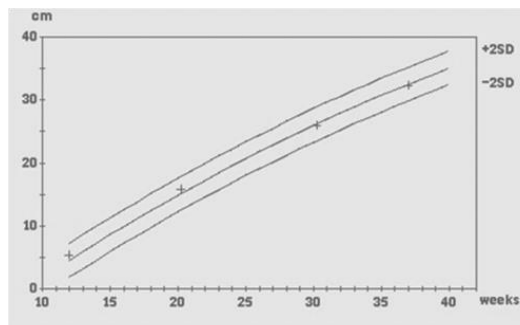
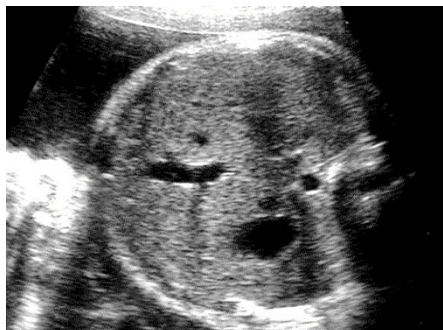Pentalogia de Cantrell

**Mês 04. Aulas Práticas.
80 pacientes agendados.**

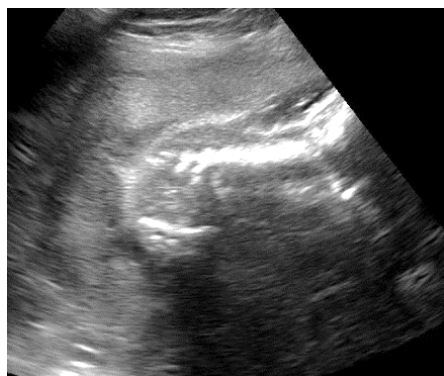Mês 05. Disciplinas:

Disciplina 1. Ultrassonografia da Gravidez de Alto Risco.

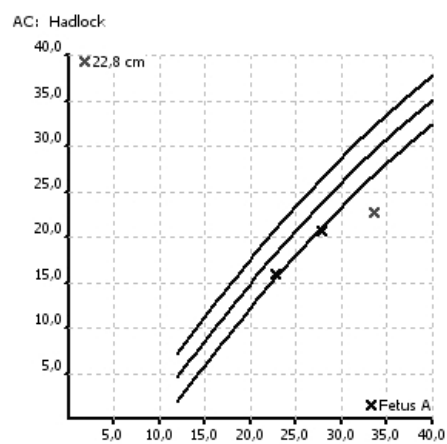
Alguns exemplos:



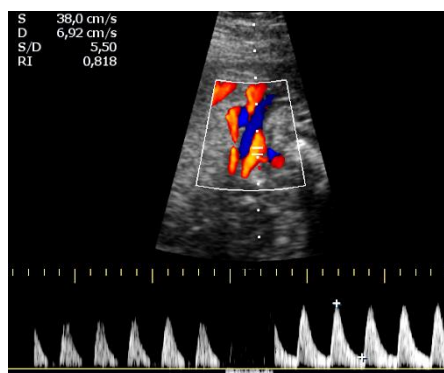
Nutrição e crescimento fetal



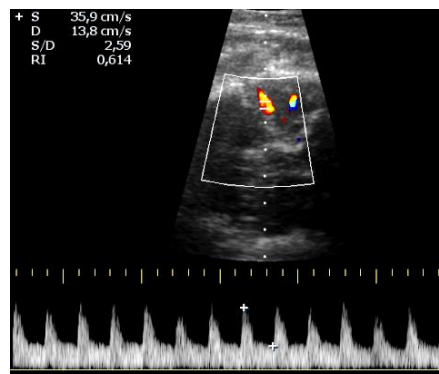Infarto placentário e oligo-hidrânio



Restrição do crescimento fetal



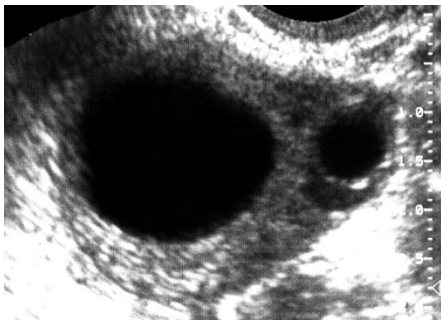
Insuficiência placentária



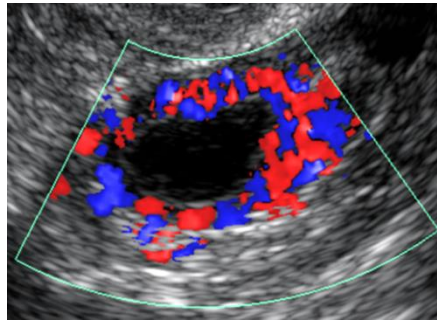
Hipóxia fetal

Disciplina 2. Diagnóstico Ecográfico da Função Ovariana.

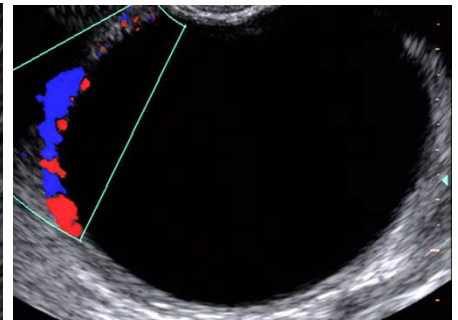
Alguns exemplos:



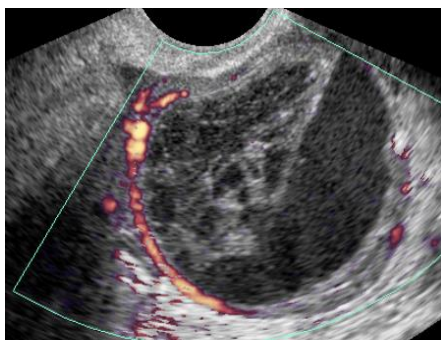
Folículo maduro



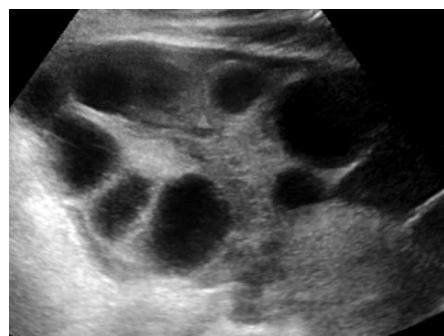Corpo lúteo normal



Folículo hidrópico



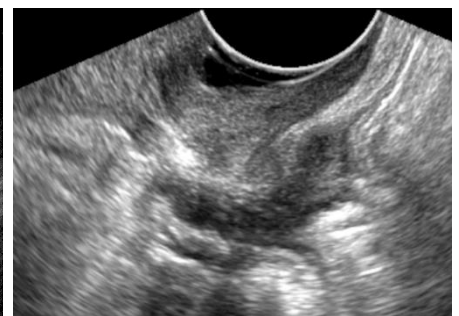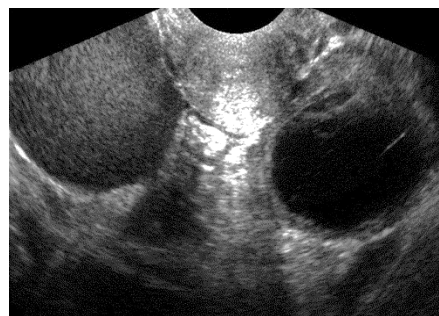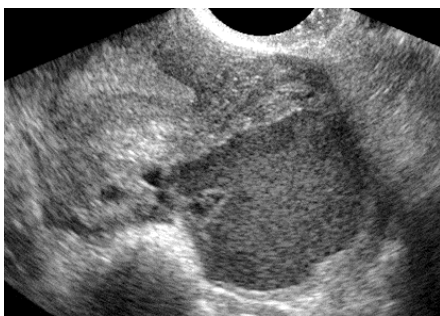Corpo lúteo hemorrágico



Indução da ovulação: hiperestimulação

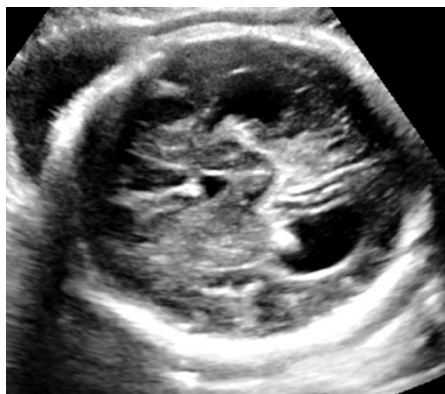Disciplina 3. Aspectos Ecográficos da Endometriose.

Alguns exemplos:

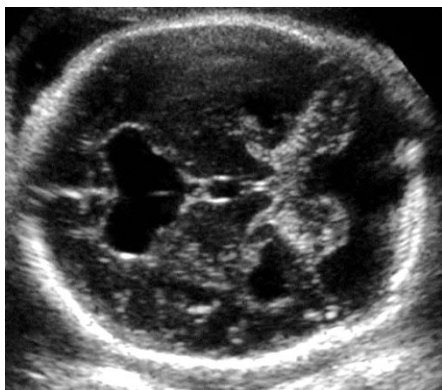

Endometriose e aderências Endometriose e anovulação Invasão: sigmoide e reto

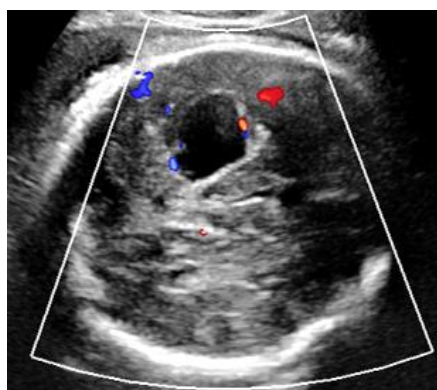
Disciplina 4. Patologia Fetal: Malformações do Sistema Nervoso Central.
Alguns exemplos:



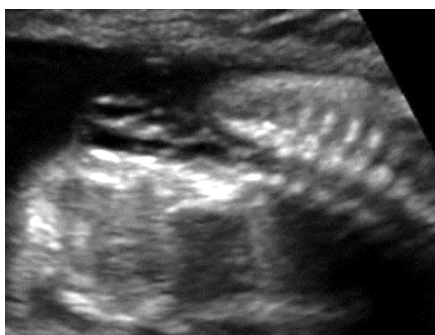
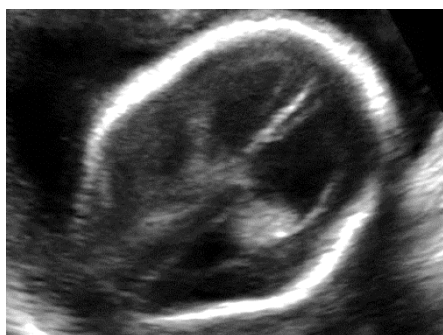
Ventriculomegalia cerebral



Dandy-Walker

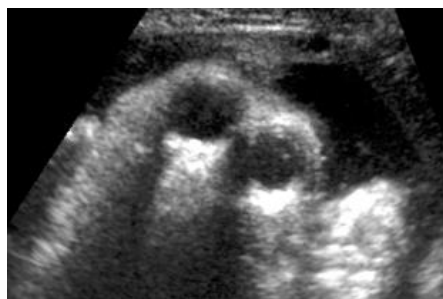


Cisto aracnoide

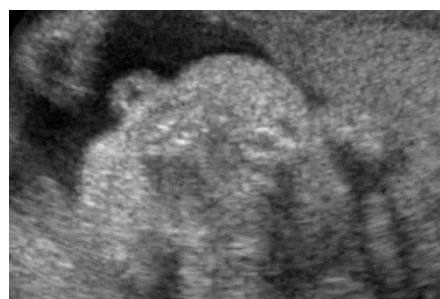

Malformação de Arnold-Chiari

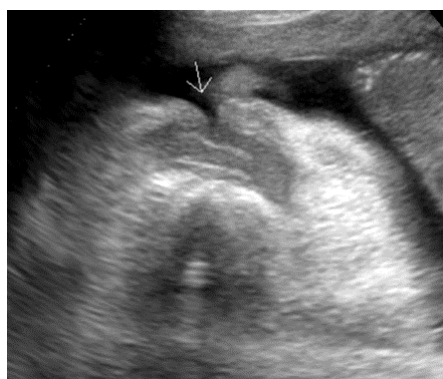Disciplina 5. Patologia Fetal: Malformações da Face.
Alguns exemplos:



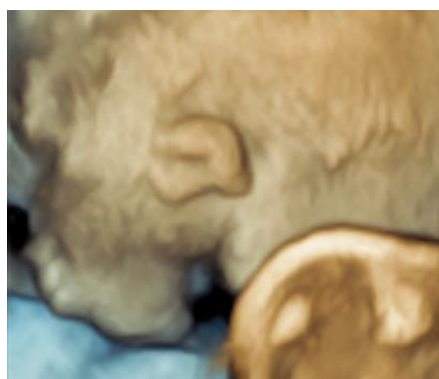
Hipotelorismo



Cebocefalia



Fenda labial

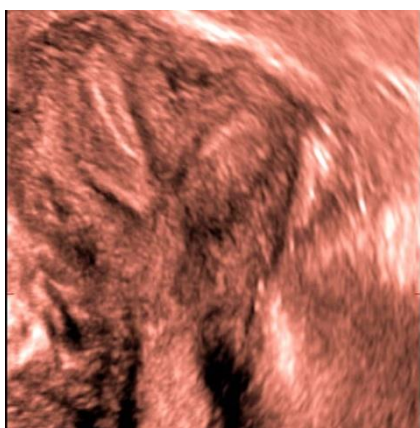


Microtia

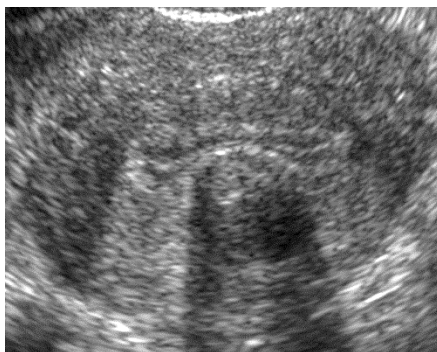
Mês 06. Aulas Práticas.
80 pacientes agendados.

Mês 07. Disciplinas:

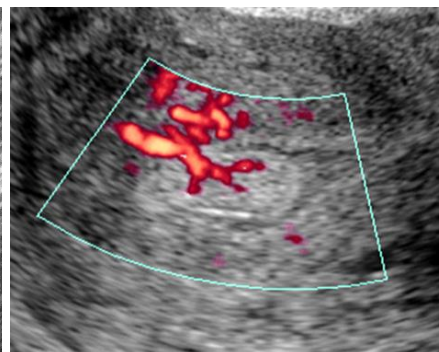
Disciplina 1. Ultrassonografia na Esterilidade Feminina.
Alguns exemplos:



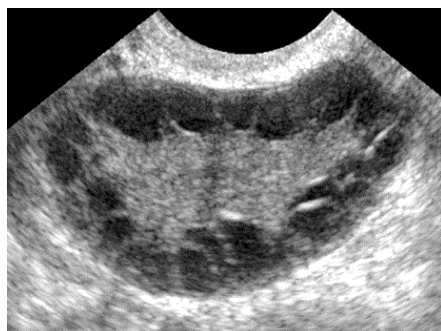Septo uterino



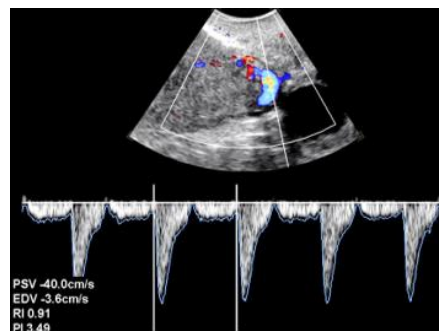
Mioma submucoso



Pólo endometrial

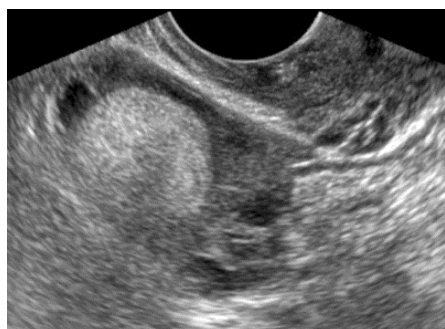

Ovário policístico

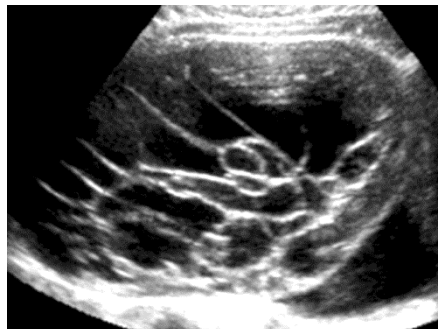

Artéria uterina anormal

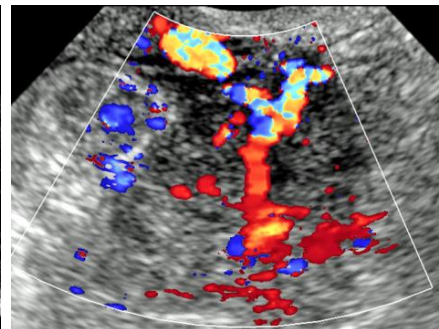
Disciplina 2. Ultrassonografia das Neoplasias Ovarianas.
Alguns exemplos:



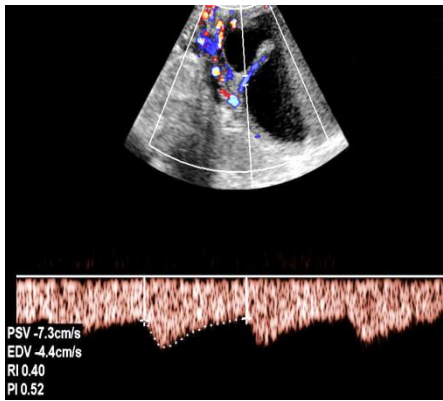
Teratoma benigno



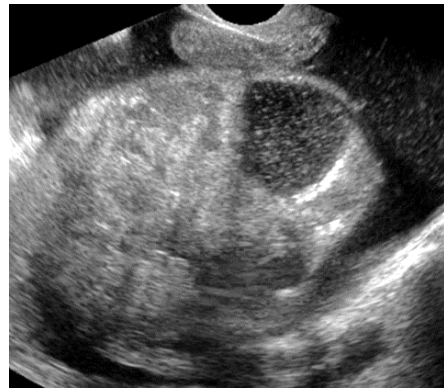
Cistoadenoma multiloculado



Mapa vascular



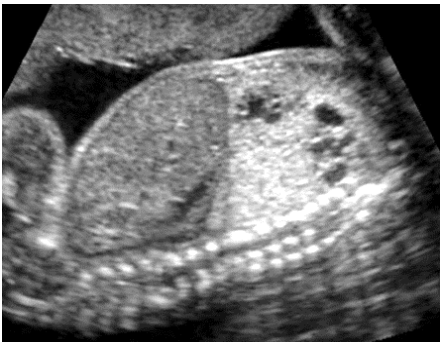Doppler: baixa impedância



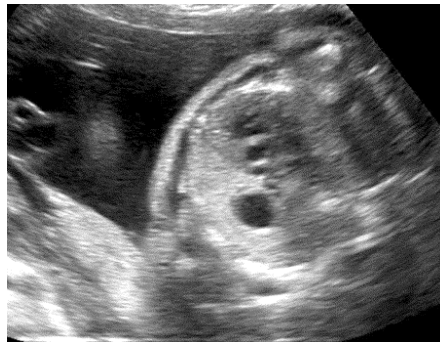Neoplasia sólida e ascite

Disciplina 3. Patologia Fetal: Anomalias Torácicas Não Cardíacas.

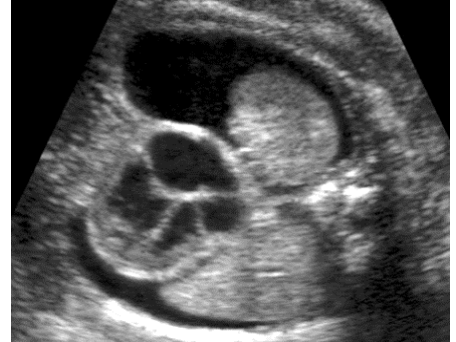
Alguns exemplos:



MF adenomatosa cística



Cisto bronquial

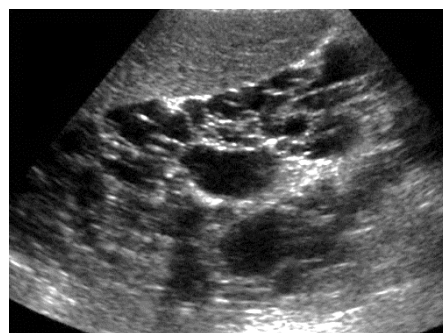
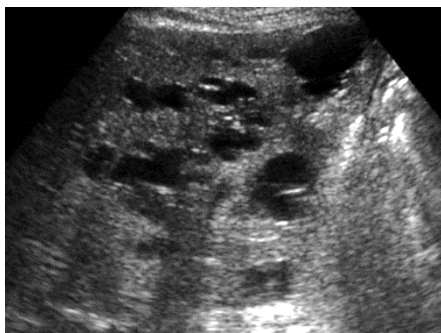

Efusão pleural bilateral

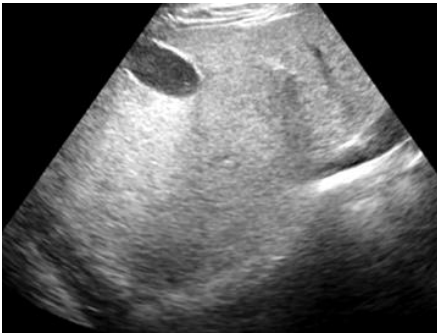
Disciplina 4. Introdução ao Doppler: Princípios, Métodos e Indicações.

Disciplina 5. Ultrassonografia do Fígado. Parte 1.

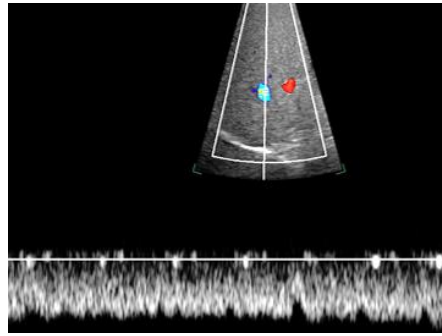
Alguns exemplos:



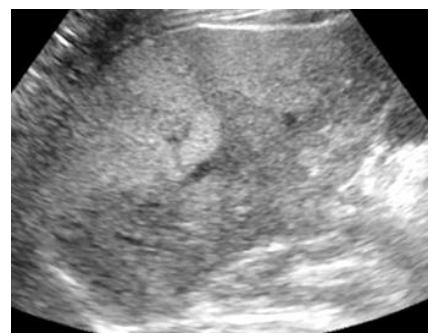
Doença policística autossômica dominante



Esteatose hepática



Veia hepática média



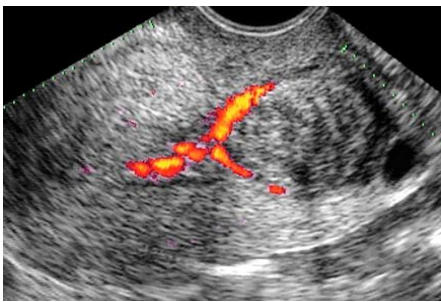
Hepatopatia tóxica

**Mês 08. Aulas Práticas.
80 pacientes agendados.**

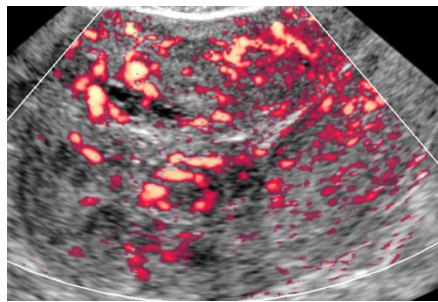
Mês 09. Disciplinas:

Disciplina 1. Hemorragia Genital Feminina.

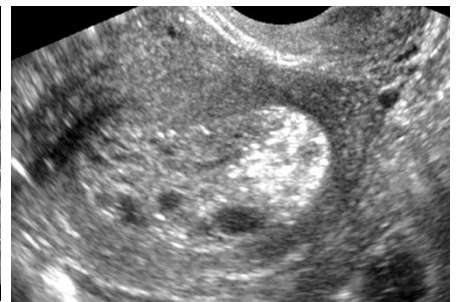
Alguns exemplos:



Mioma parido



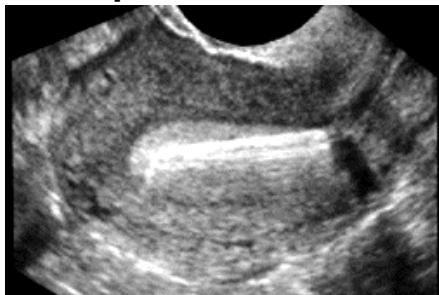Adenomiose



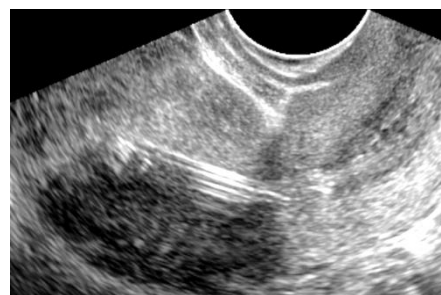Hiperplasia endometrial

Disciplina 2. O Dispositivo Intrauterino.

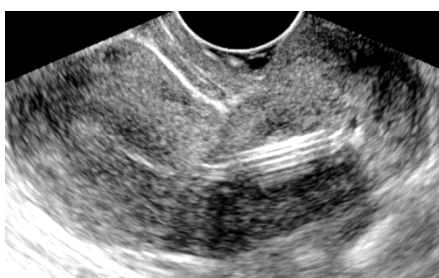Alguns exemplos:



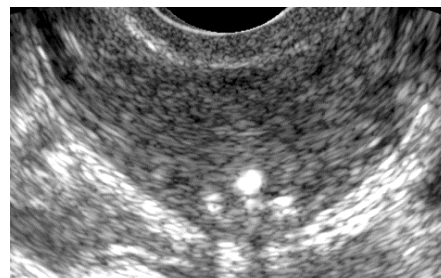
Cobre



Progesterona



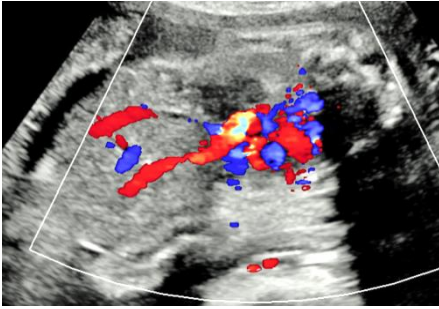
Dentro do canal cervical



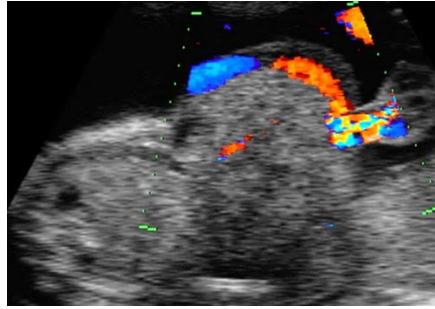
Dentro do miométrio

Disciplina 3. Patologia Fetal: Anomalias da Cavidade Celômica.

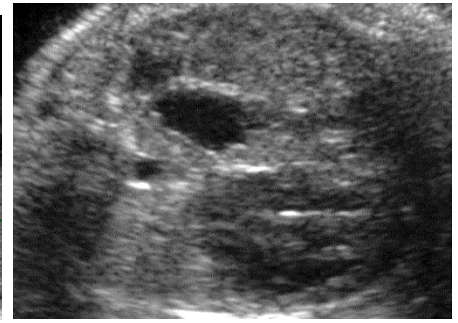
Alguns exemplos:



Pentalogia de Cantrell



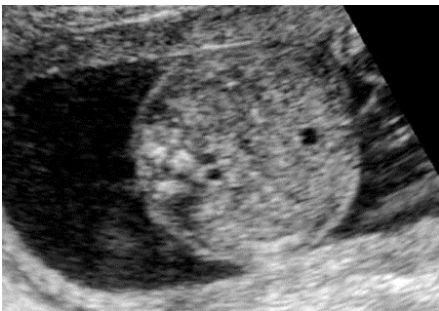
Onfalocele



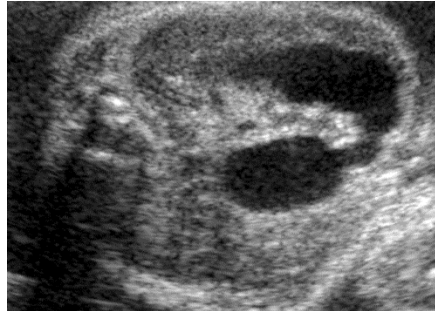
Hérnia diafragmática

Disciplina 4. Patologia Fetal: Anomalias do Aparelho Digestivo.

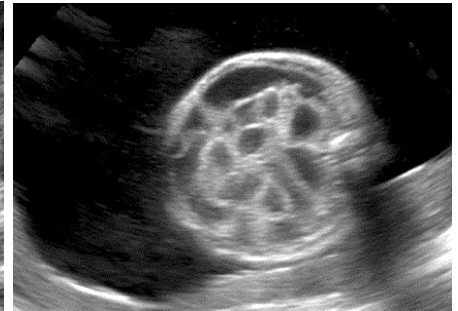Alguns exemplos:



Obstrução do esôfago



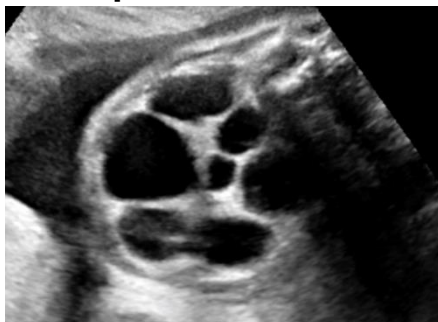Obstrução do duodeno



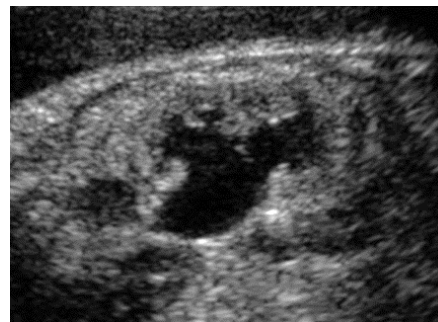
Obstrução do íleo

Disciplina 5. Patologia Fetal: Malformações Urogenitais.

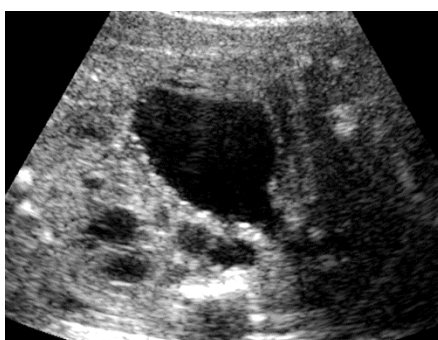Alguns exemplos:



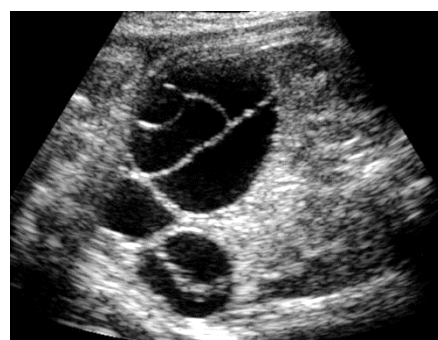Displasia renal



Hidronefrose



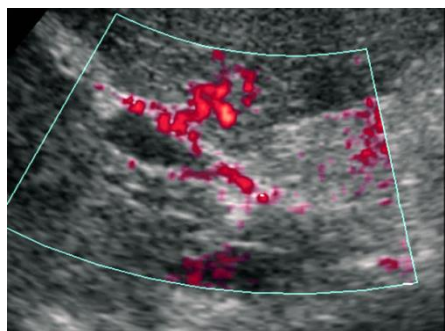
Obstrução uretral



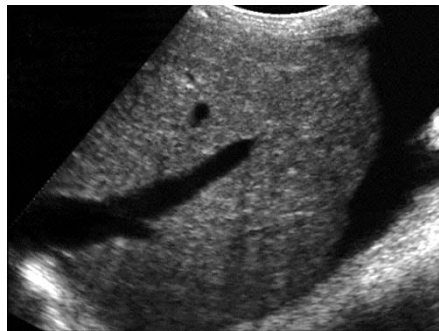Cisto ovariano bilateral

Disciplina 6. Ultrassonografia do Fígado. Parte 2.

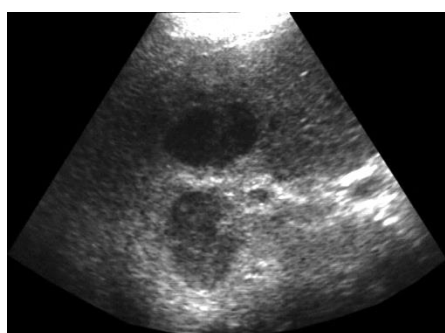
Alguns exemplos:



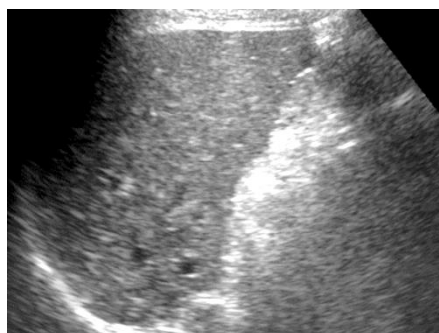Trombose da veia porta



Insuficiência cardíaca



Abscessos hepáticos



Malária

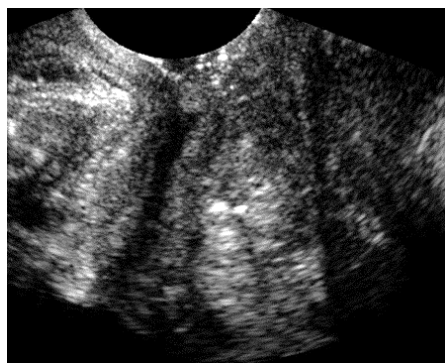Mês 10. Aulas Práticas.

80 pacientes agendados.

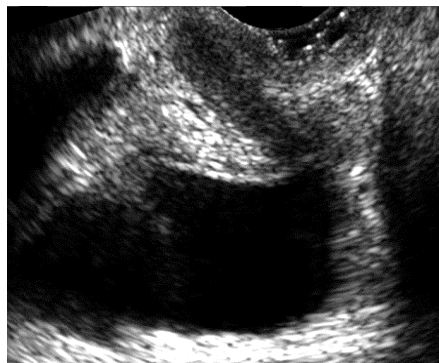Mês 11. Disciplinas:

Disciplina 1. Patologia da Uretra Feminina.

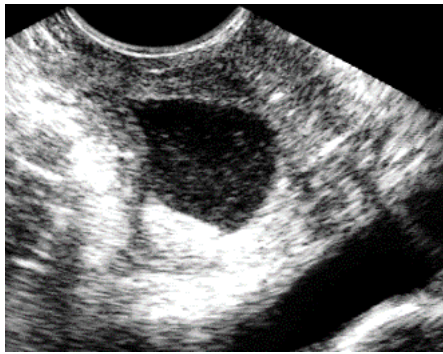
Alguns exemplos:



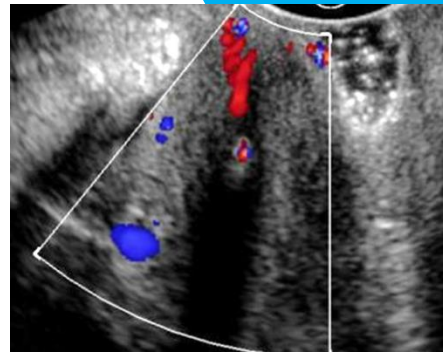
Anatomia da uretra



Incontinência urinária



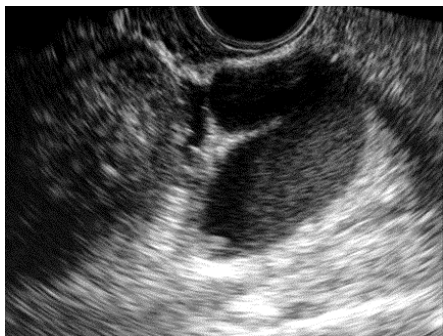Divertículo



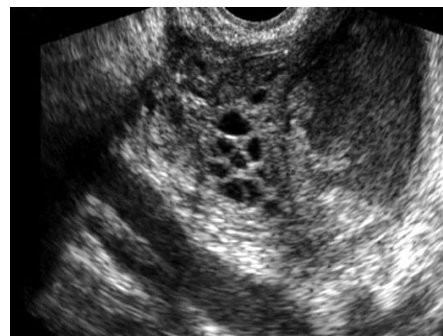Pólipo

Disciplina 2. Doença Inflamatória Pélvica.

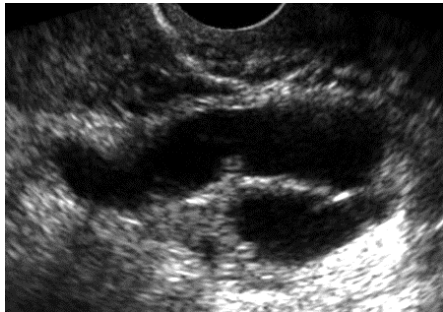
Alguns exemplos:



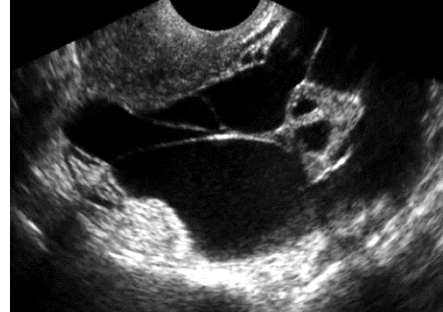Piossalpingite aguda



Abscesso tuboovariano



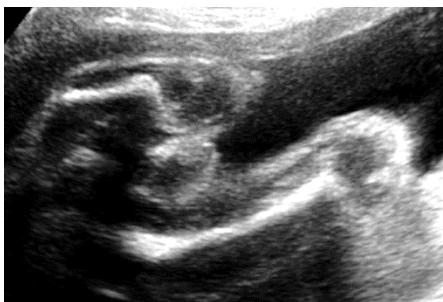Hidrossalpinge



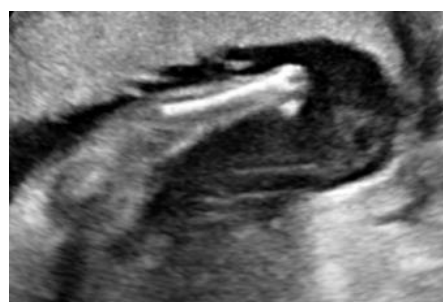Cisto de inclusão peritoneal

Disciplina 3. Patologia Fetal: Malformações Esqueléticas.

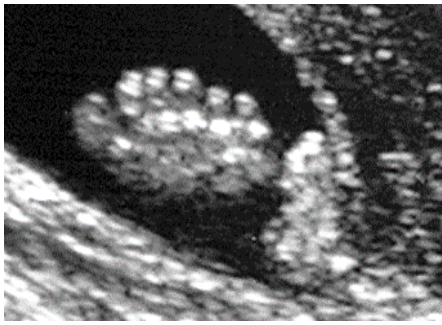
Alguns exemplos:



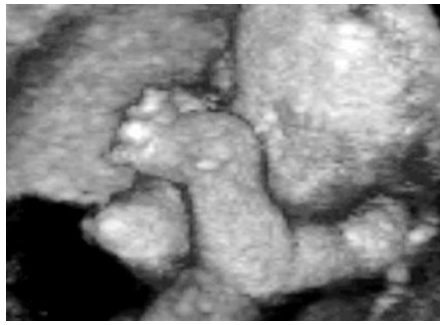
Rizomelia



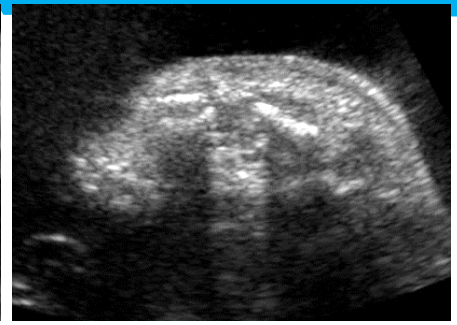Apodia



Polidactilia



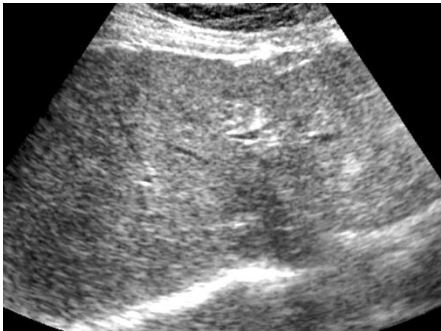
Rizomelia e artrogripose



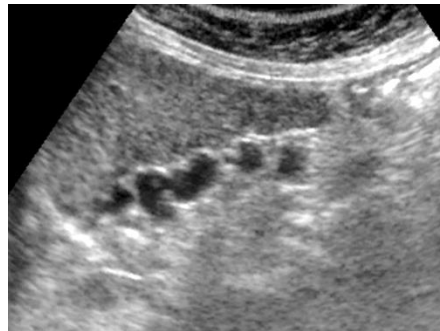
Micromelia

Disciplina 4. Patologia Hepática. Parte 3.

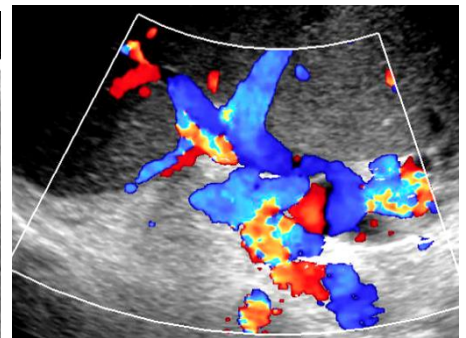
Alguns exemplos:



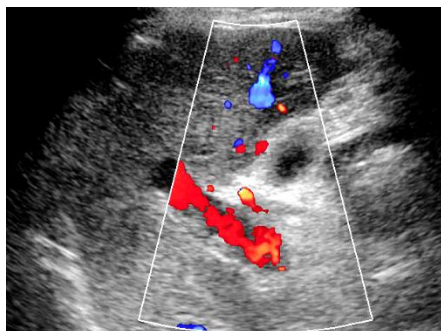
Cirrose



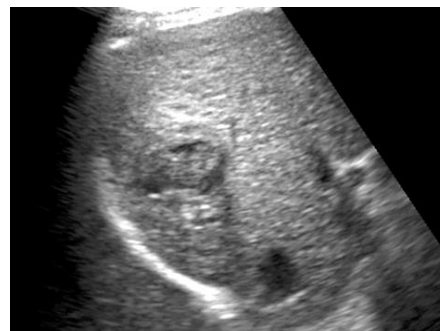Varizes gástricas



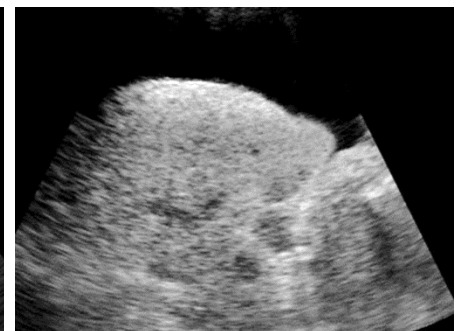Esplenomegalia: varizes



Cirrose: trombose portal



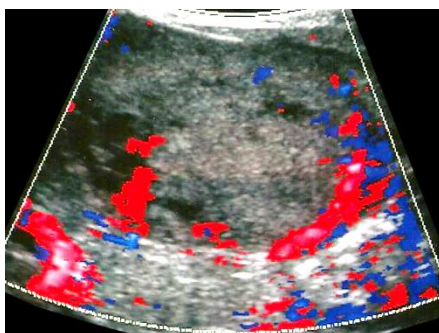
Cirrose: carcinoma



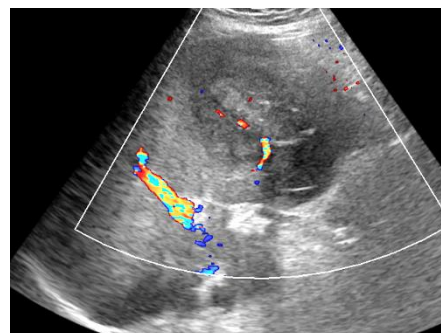
Cirrose: ascite

Disciplina 5. Patologia Hepática. Parte 4.

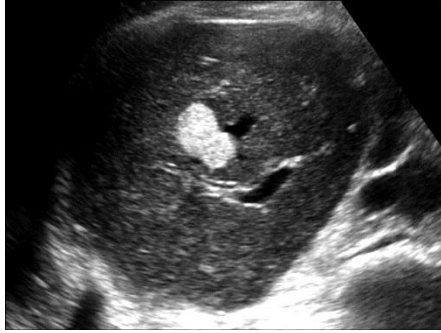
Alguns exemplos:



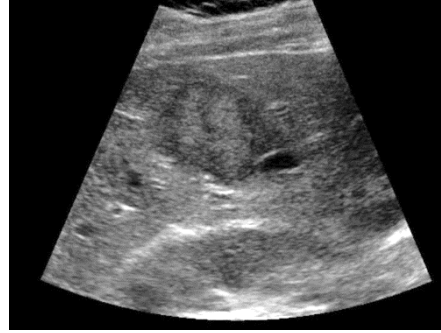Adenoma



Carcinoma



Hemangioma



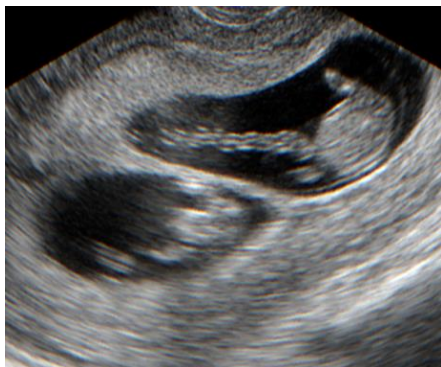Metástase

**Mês 12. Aulas Práticas.
80 pacientes agendados.**

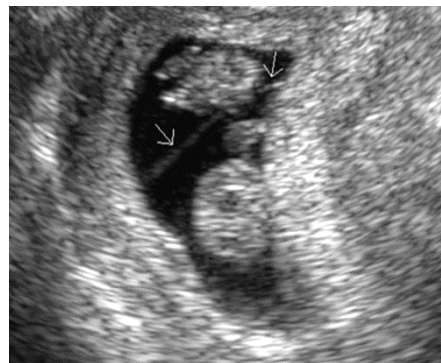Mês 13. Psicologia Médica.

Mês 14. Disciplinas:

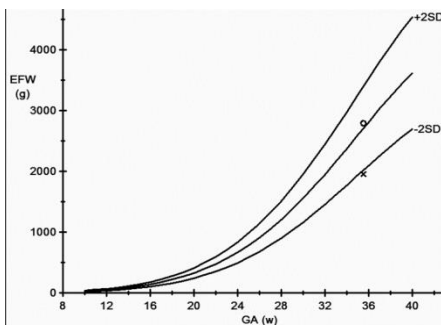
**Disciplina 1. Gestação Múltipla.
Alguns exemplos:**



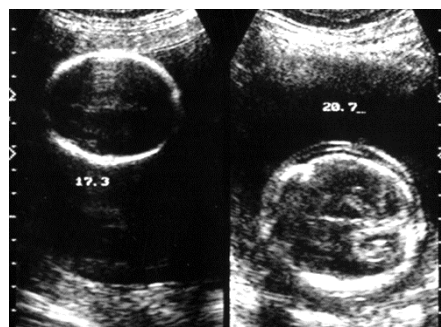
Gemelar dicoriônico



Gemelar monocoriônico



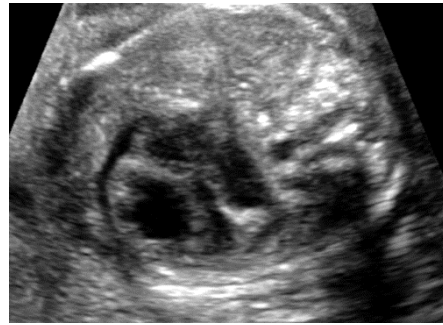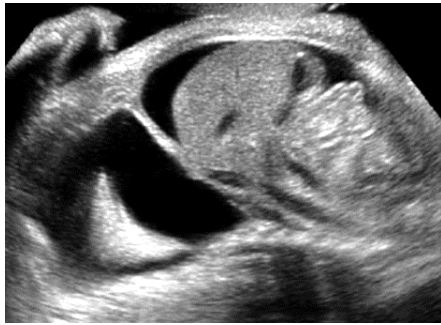Restrição do crescimento



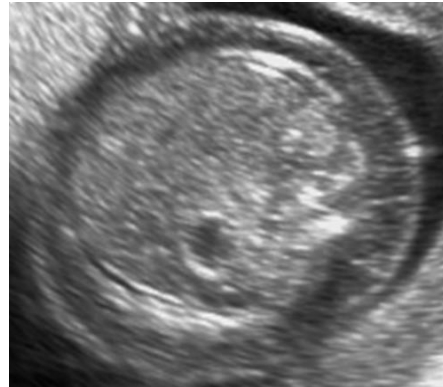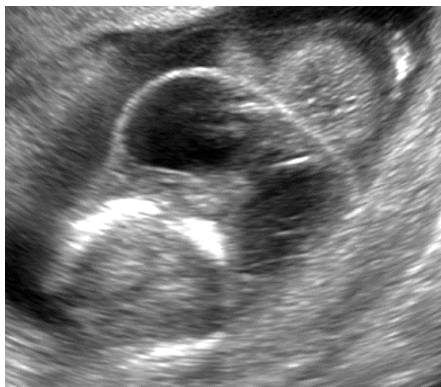Transfusão fetofetal

Disciplina 2. Hidropisia Fetal.

Alguns exemplos:



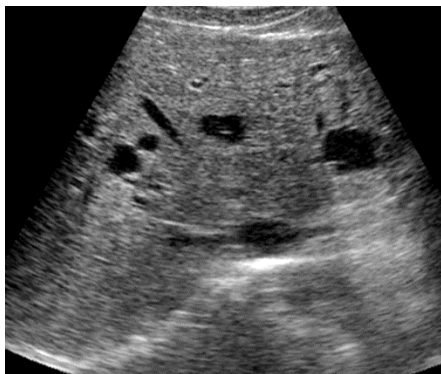Hidropisia: três cavidades serosas



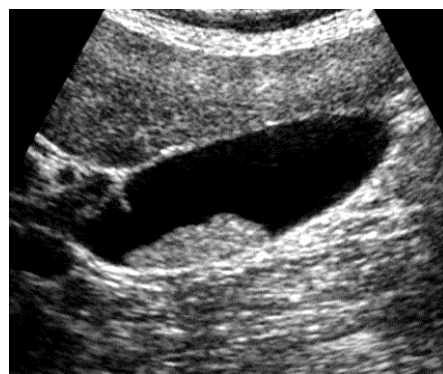Displasia linfática

Disciplina 3. Patologia da Vesícula Biliar e dos Ductos Biliares. Parte 1.

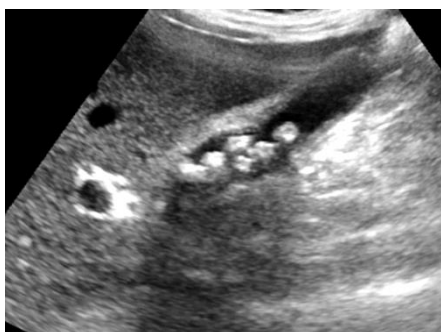
Alguns exemplos:



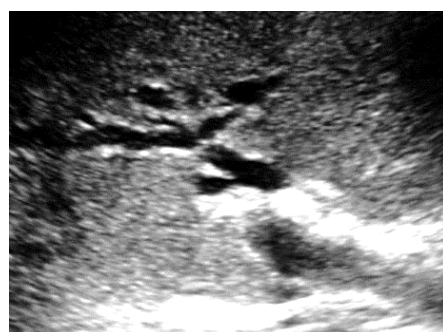Doença de Caroli



Bile tumefacta

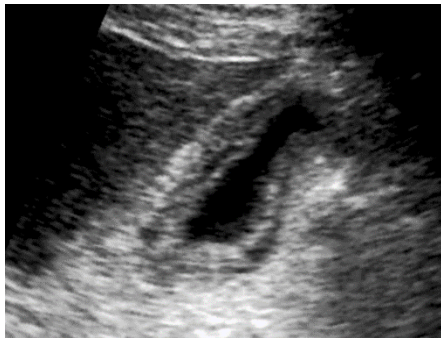

Litíase vesicular

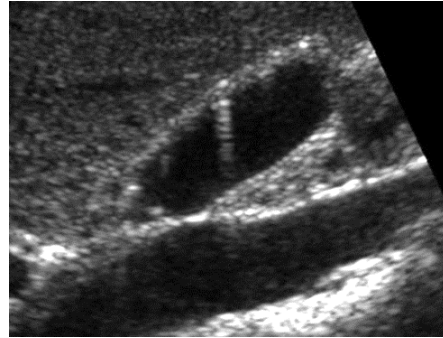


Litíase biliar: obstrução

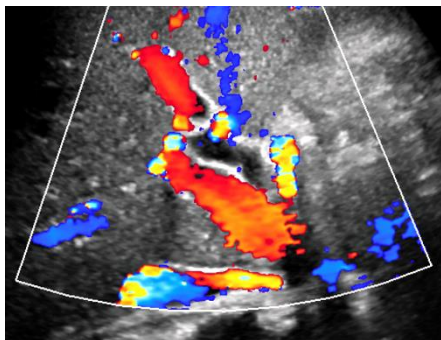
Disciplina 4. Patologia da Vesícula Biliar e dos Ductos Biliares. Parte 2.
Alguns exemplos:



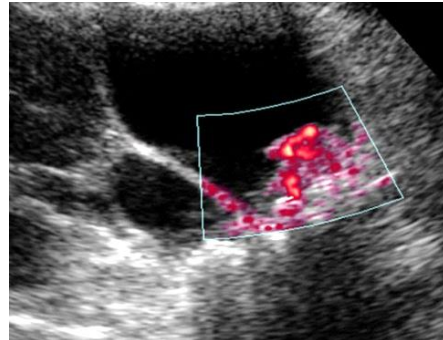
Colecistite aguda



Colesterolose

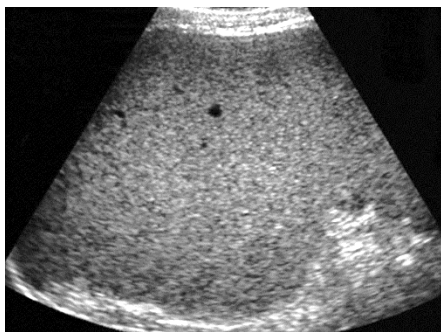

Colédoco obstruído

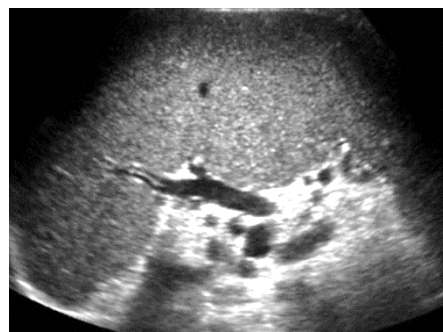

Carcinoma da vesícula

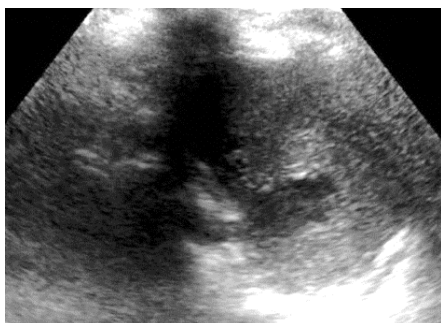
Disciplina 5. Patologia do Baço.
Alguns exemplos:



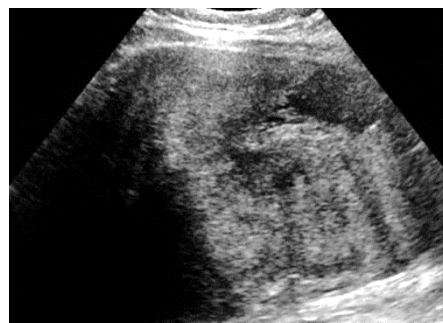Esplenomegalia inflamatória



Hipertensão portal

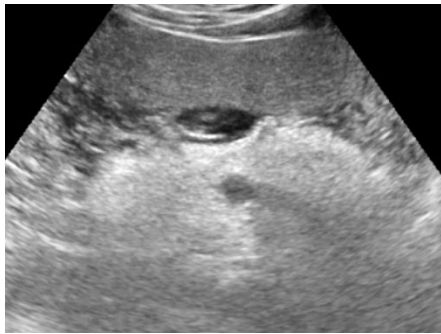

Trauma

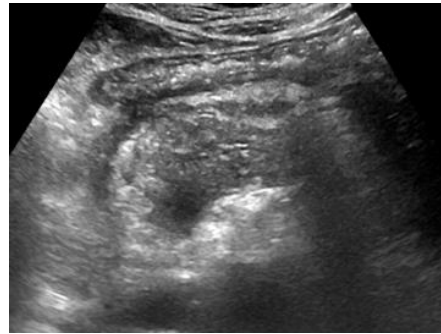


Neoplasia

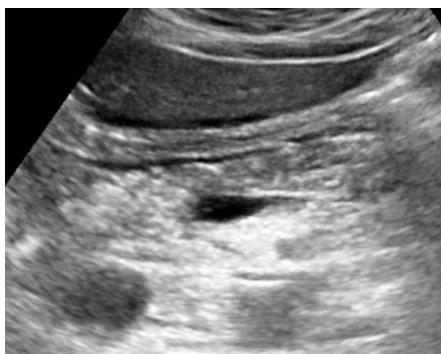
**Disciplina 6. Patologia do Pâncreas.
Alguns Exemplos:**



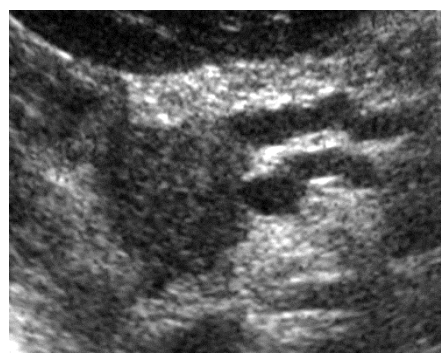
Esteatose pancreática



Pancreatite aguda



Pancreatite crônica

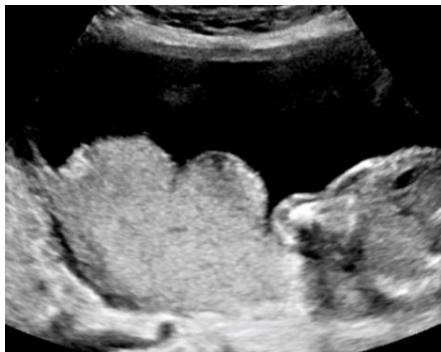

Carcinoma

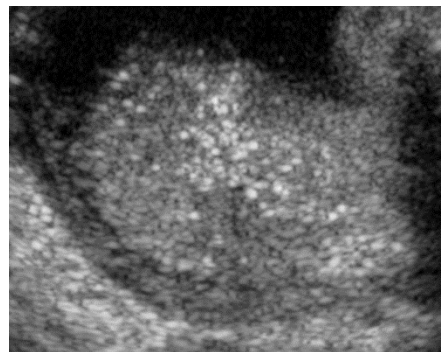
**Mês 15. Aulas Práticas.
80 pacientes agendados.**

Mês 16. Disciplinas:

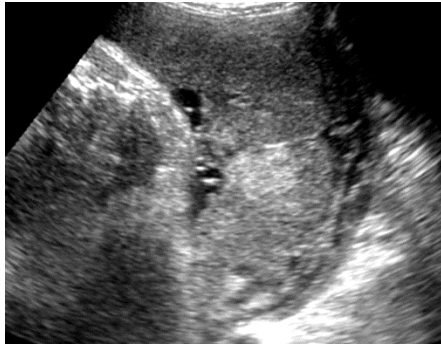**Disciplina 1. Patologia da Placenta.
Alguns exemplos:**



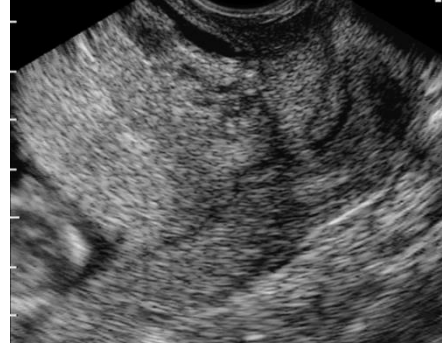Placenta lobulada (“bump”)



Infecção



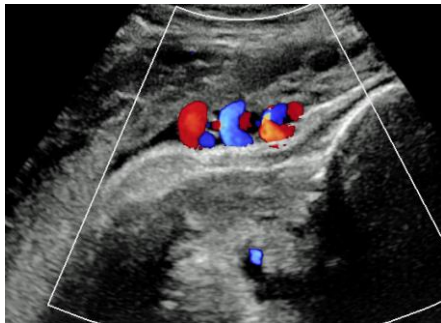
Infarto



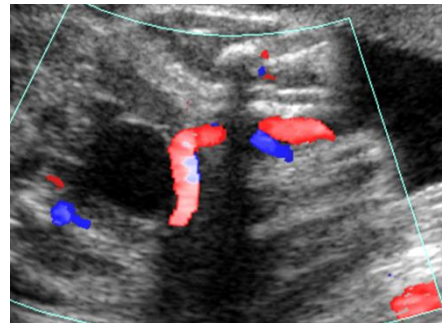
Placenta prévia

Disciplina 2. Patologia do Cordão Umbilical

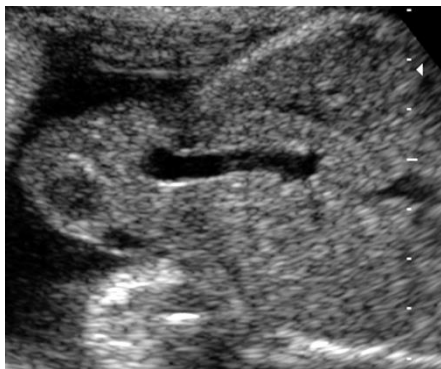
Alguns exemplos:



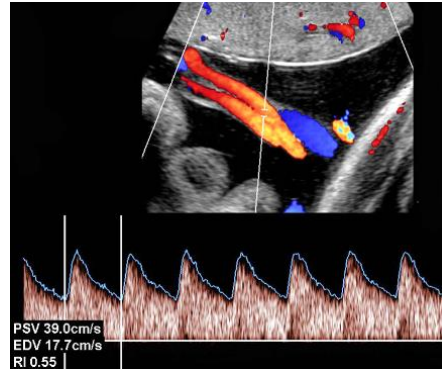
Circulares cervicais



Artéria umbilical única



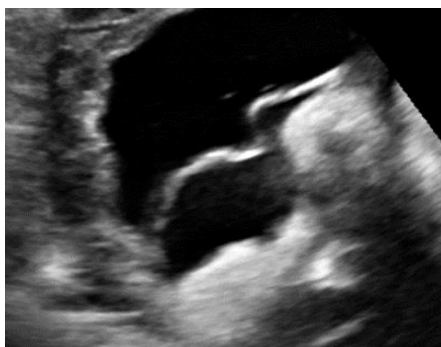Hérnia umbilical



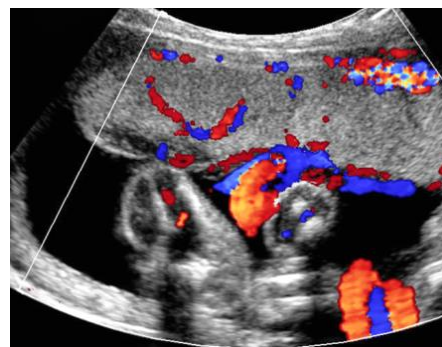
Doppler umbilical

Disciplina 3. Ultrassonografia da Cavidade Amniótica.

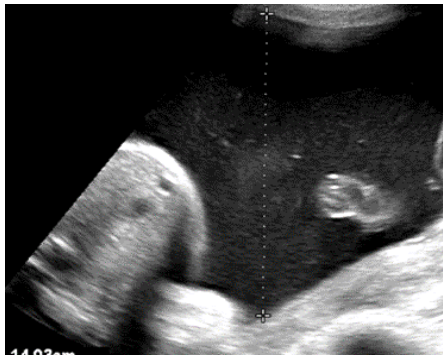
Alguns exemplos:



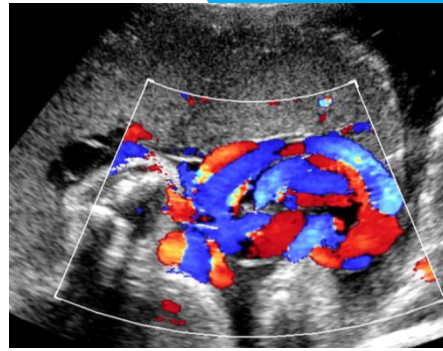
Banda amniótica



Volume amniótico



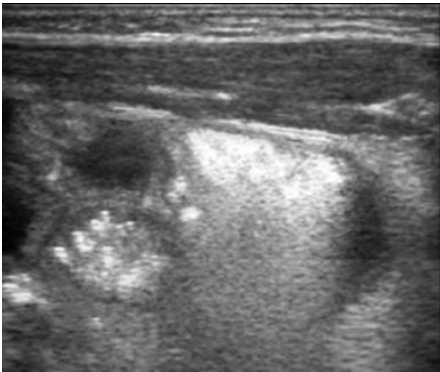
Poli-hidrânio



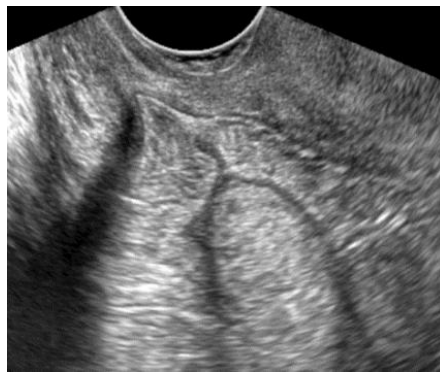
Oligo-hidrânio

Disciplina 4. Ultrassonografia do Tubo Digestivo.

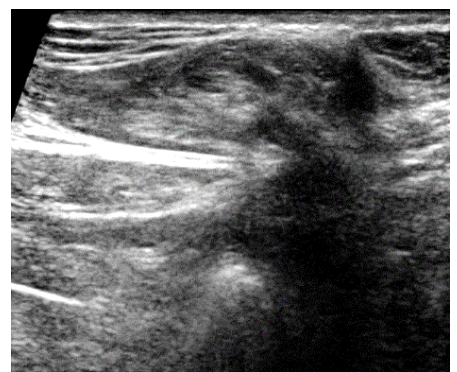
Alguns exemplos:



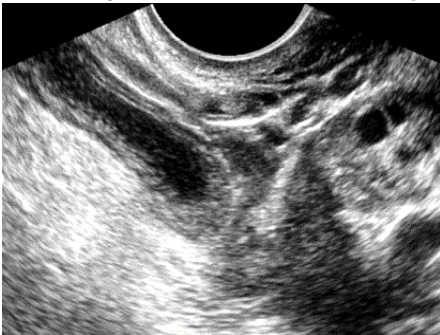
Doença de Hirschsprung



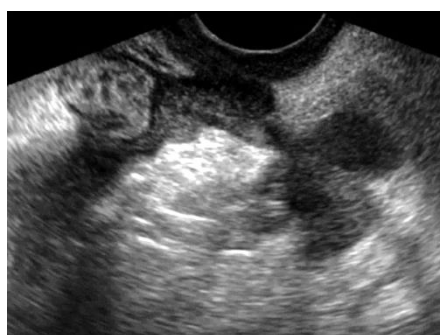Aderências intestinais



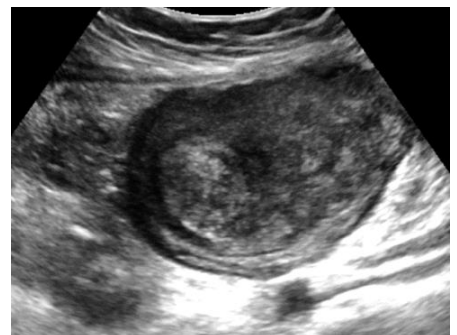
Hérnia intestinal



Apendicite aguda



Diverticulite aguda



Carcinoma intestinal

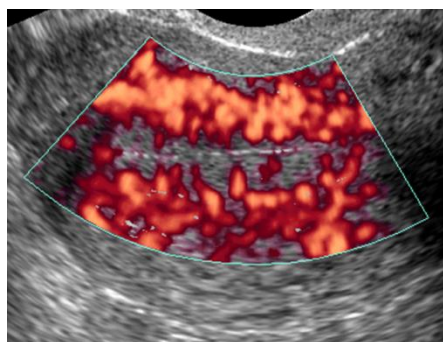
Mês 17. Aulas Práticas.

80 pacientes agendados.

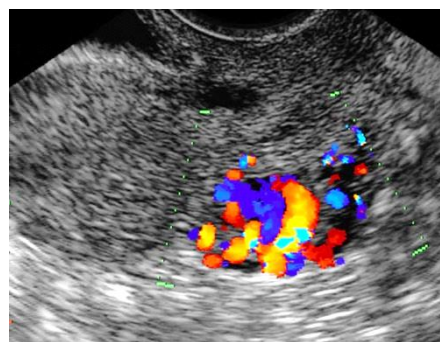
Mês 18. Disciplinas:

Disciplina 1. Doppler na Patologia Uterina.

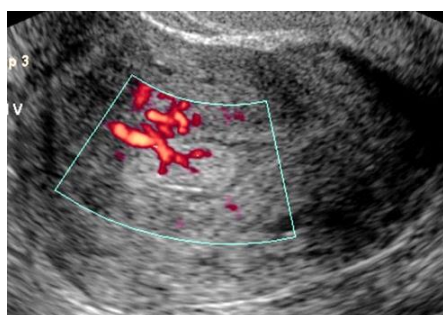
Alguns exemplos:



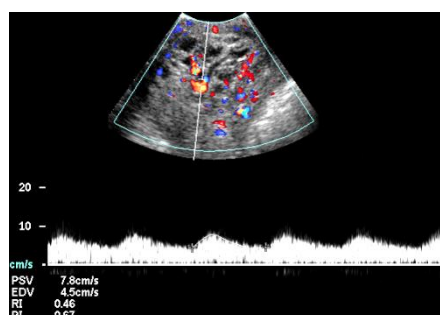
Mapa vascular



Malformação vascular



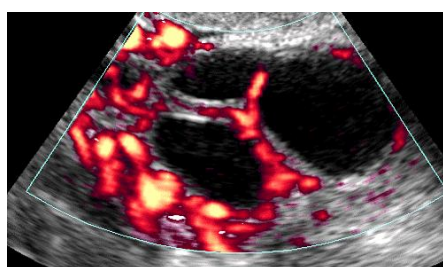
Pólipo endometrial



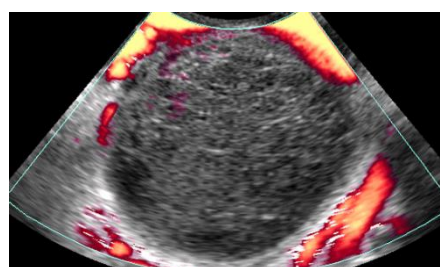
Proliferação endometrial anormal

Disciplina 2. Doppler na Patologia Ovariana.

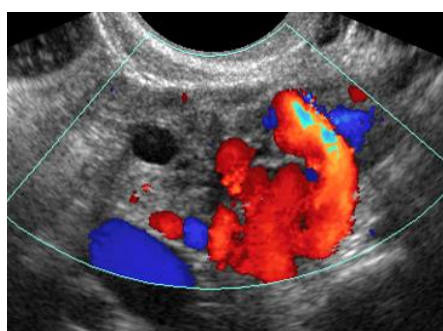
Alguns exemplos:



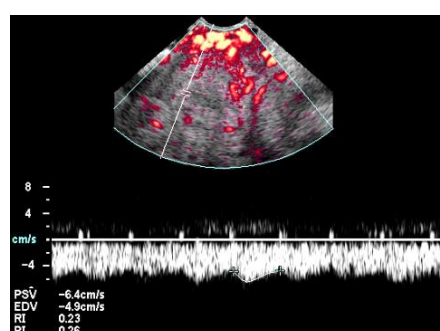
Estimulação ovariana



Corpo lúteo hemorrágico



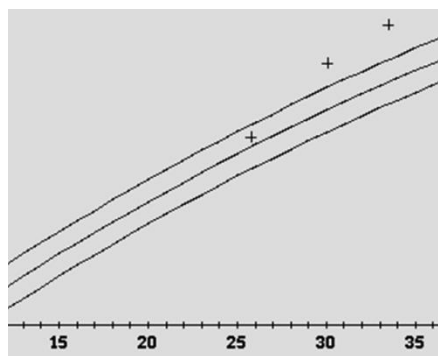
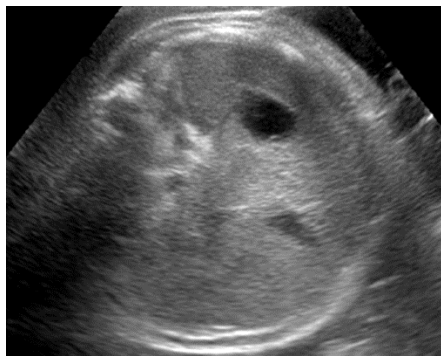Congestão venosa



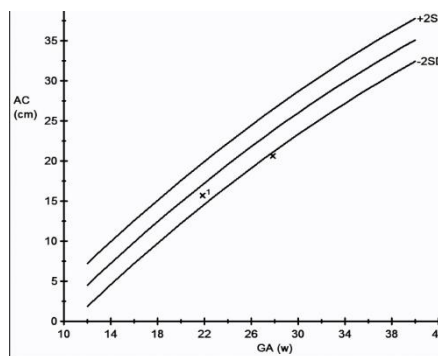
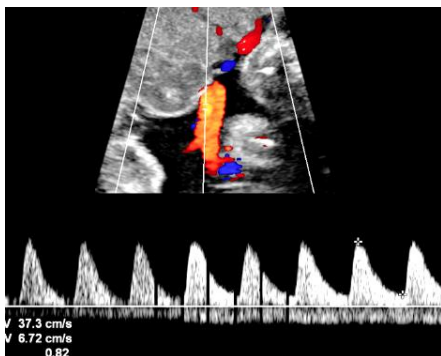
Carcinoma ovariano

Disciplina 3. Avaliação do Crescimento Fetal.

Alguns exemplos:



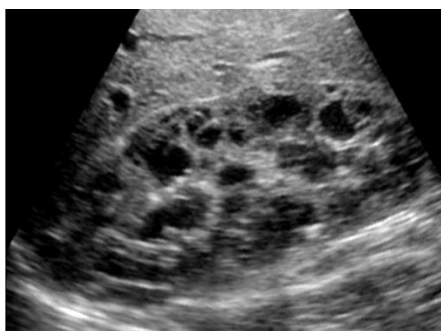
Diabete gestacional



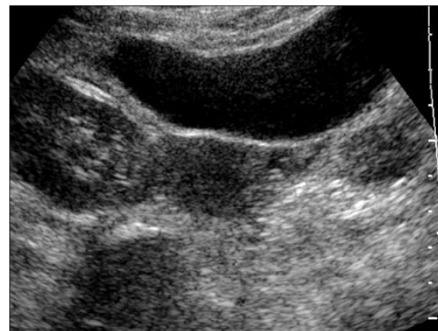
Insuficiência placentária

Disciplina 4. Ultrassonografia do Aparelho Urinário. Parte 1.

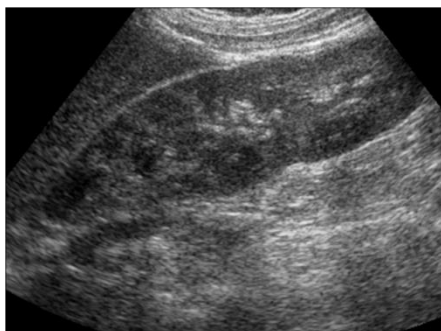
Alguns exemplos:



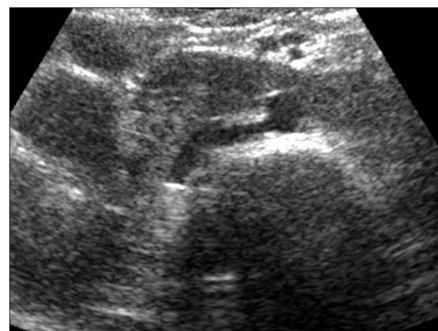
Doença policística



Rim pélvico



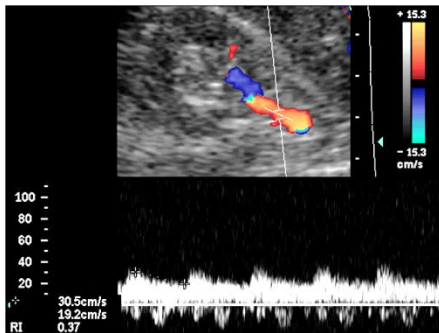
Fusão renal



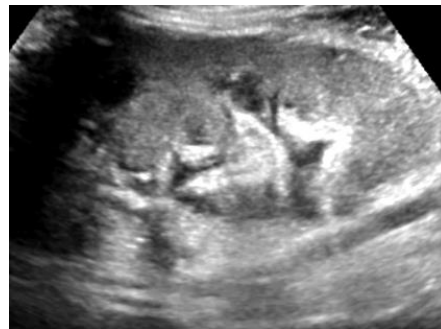Rins em ferradura

Disciplina 5. Ultrassonografia do Aparelho Urinário. Parte 2.

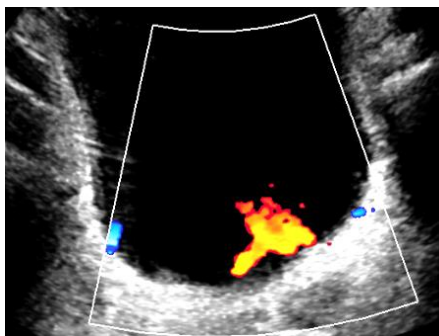
Alguns exemplos:



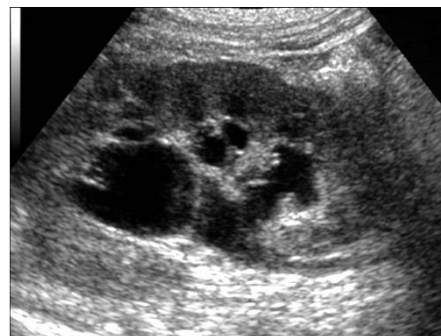
Estenose arterial



Duplicação piélica



Três ureteres

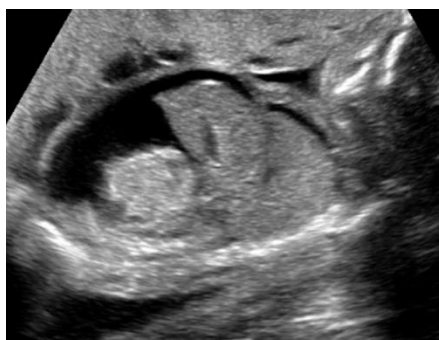

Hidronefrose

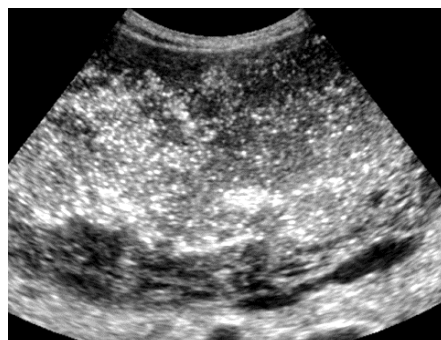
Mês 19. Aulas Práticas.
80 pacientes agendados.

Mês 20. Disciplinas:

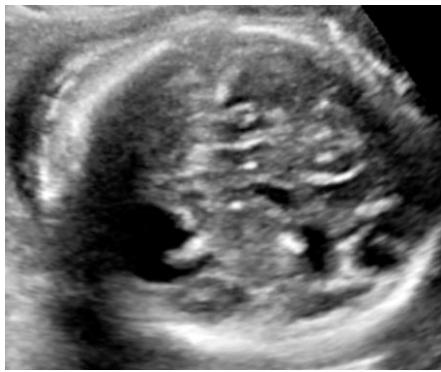
Disciplina 1. Marcadores Ecográficos das Infecções Fetais.
Alguns exemplos:



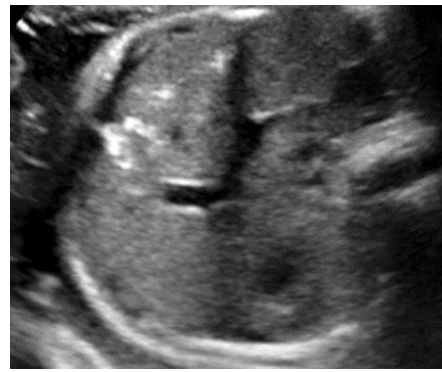Hidropisia



Placentite

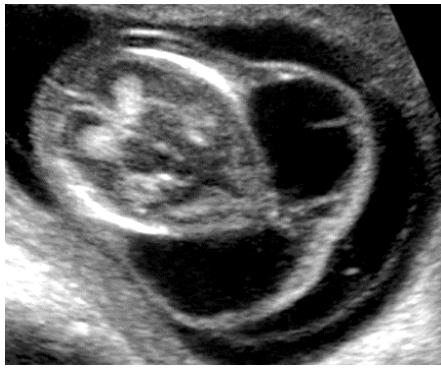

Encefalite

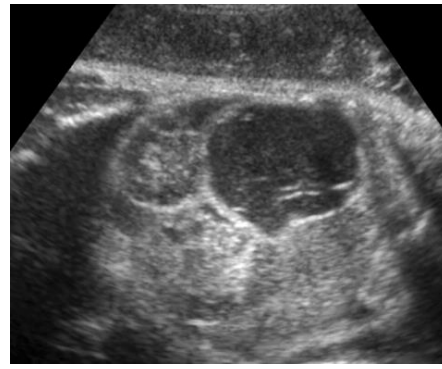


Hepatite

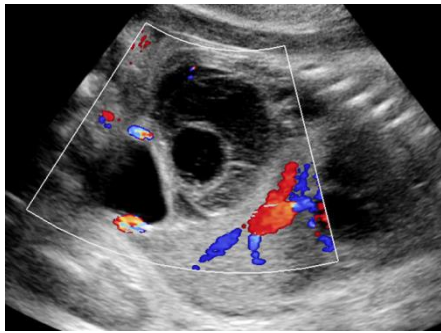
Disciplina 2. Patologia Fetal: Tumores.
Alguns exemplos:



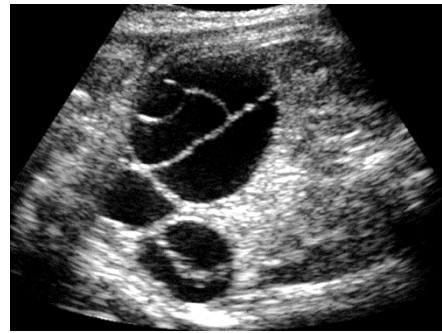
Linfangioma



Suprarrenal

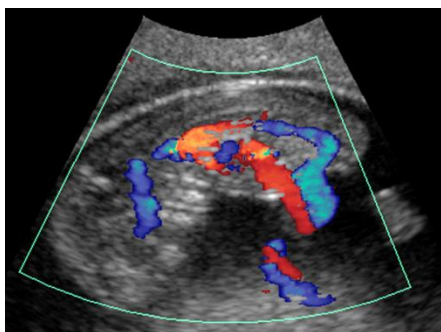


Teratoma

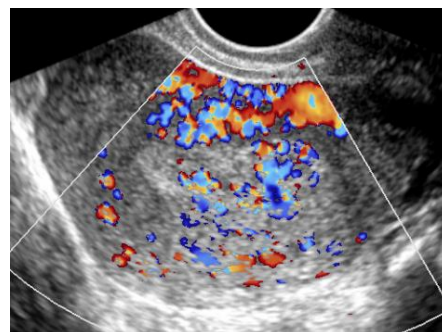


Ovários

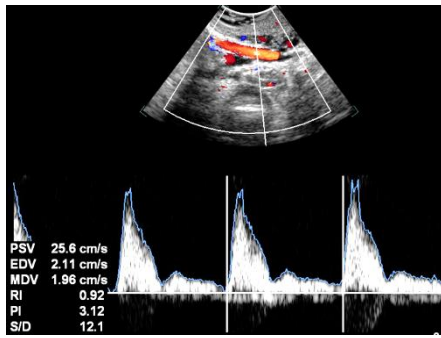
Disciplina 3. Doppler em Obstetrícia. Parte 1.
Alguns exemplos:



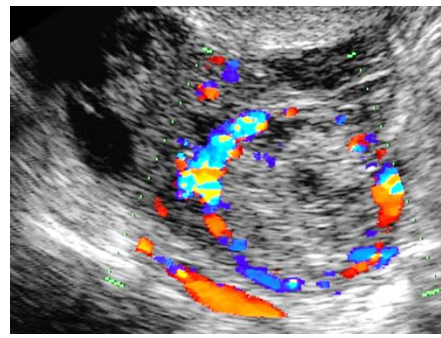
Ducto venoso



Aborto incompleto

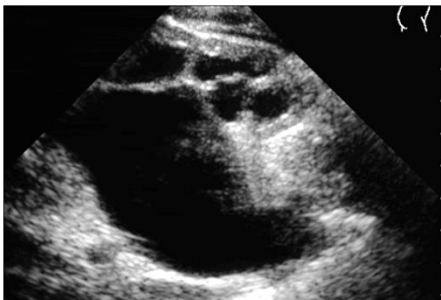

Artéria uterina anormal

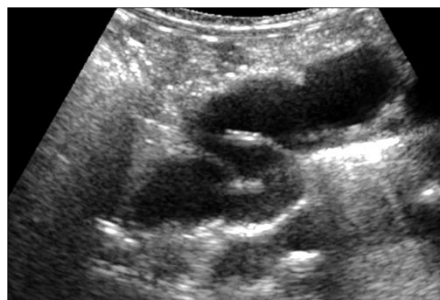

Gravidez ectópica

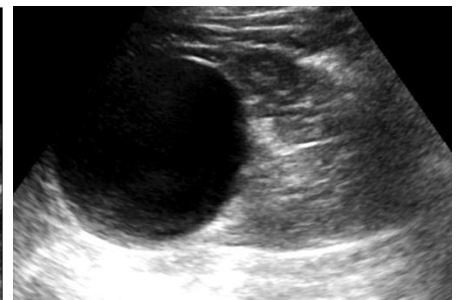Disciplina 4. Ultrassonografia do Aparelho Urinário. Parte 3.
Alguns exemplos:



Obstrução da JUP

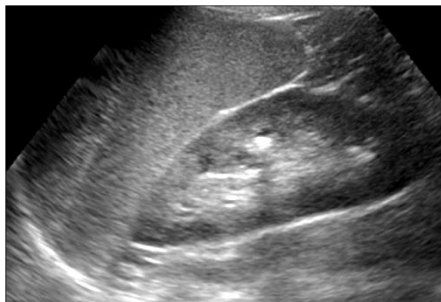


Megadolicoureter

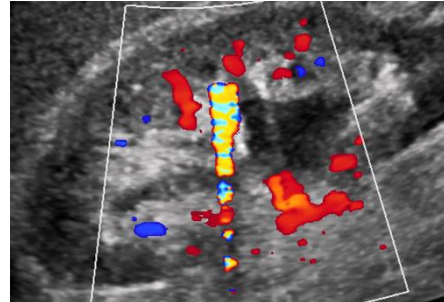


Cisto simples

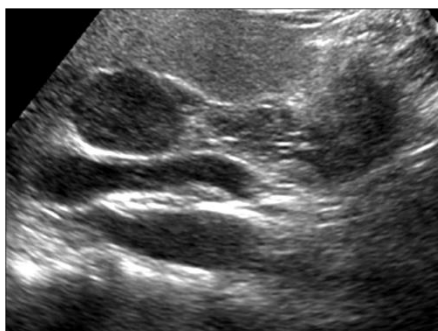
Disciplina 5. Ultrassonografia do Aparelho Urinário. Parte 4.
Alguns exemplos:



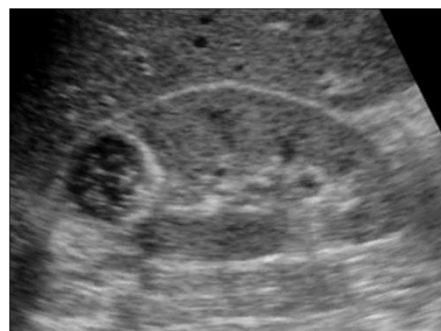Cálculo renal



Cálculo: reverberação



Ureter: cálculo

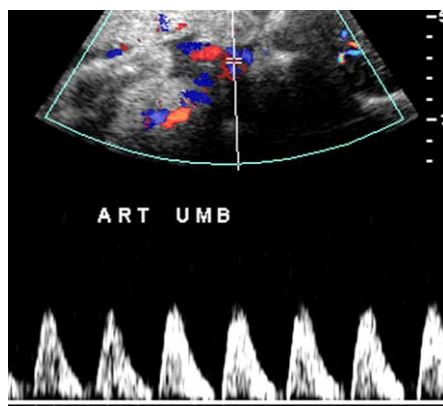


Pielonefrite: abscesso

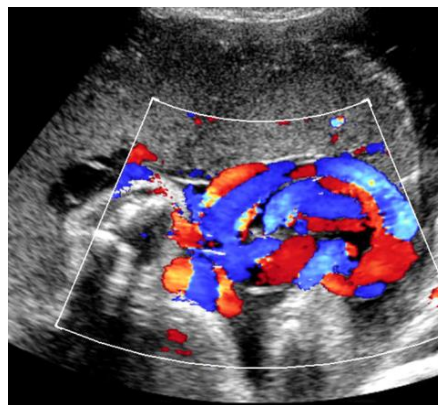
Mês 21. Disciplinas:

Disciplina 1. Doppler em Obstetrícia. Parte 2.

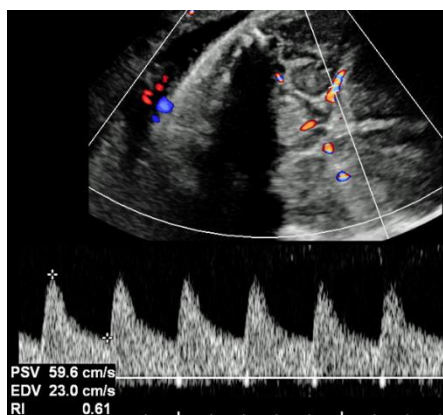
Alguns exemplos:



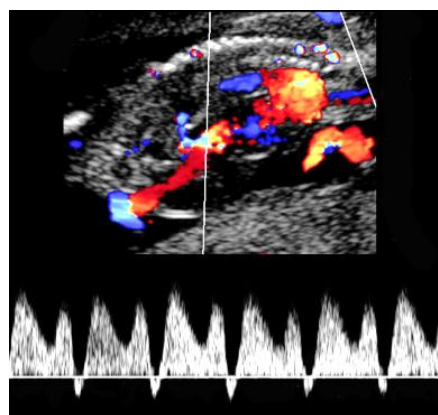
Insuficiência placentária



Oligo-hidrânio



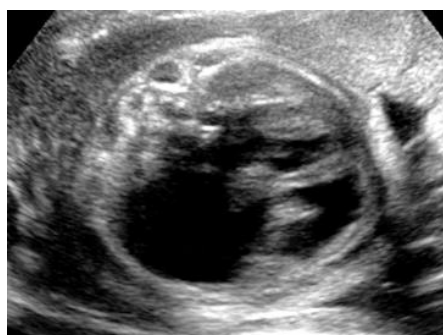Hipóxia



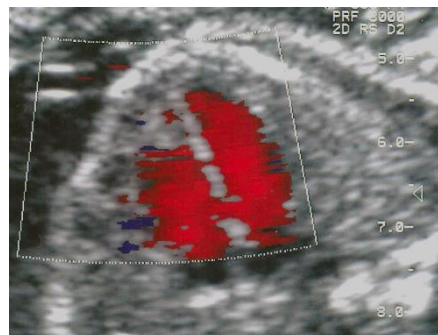
Acidose metabólica

Disciplina 2. Patologia Fetal: Anomalias Cardiovasculares.

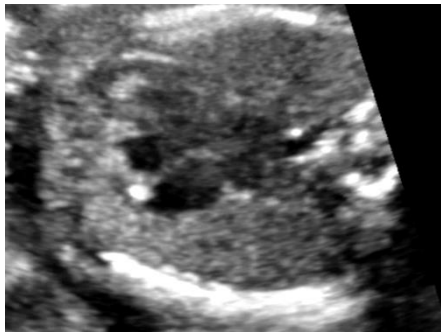
Alguns exemplos:



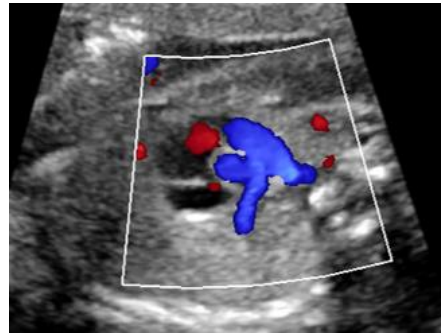
Cardiomegalia



CIV

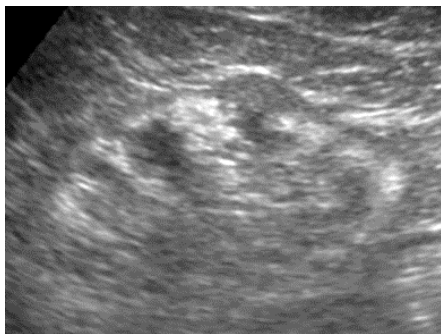


Endocardite

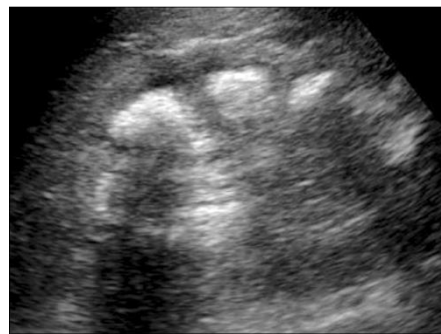

Dupla via de saída

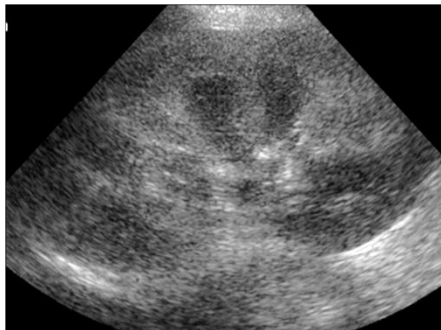
Disciplina 3. Ultrassonografia do Aparelho Urinário. Parte 5. Alguns exemplos:



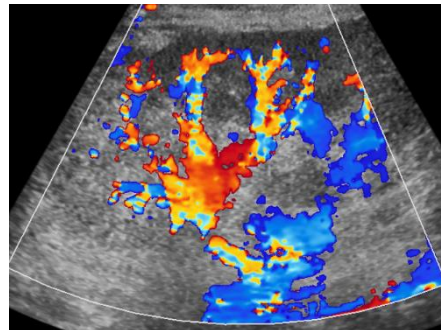
Nefropatia crônica



Tubulopatia crônica

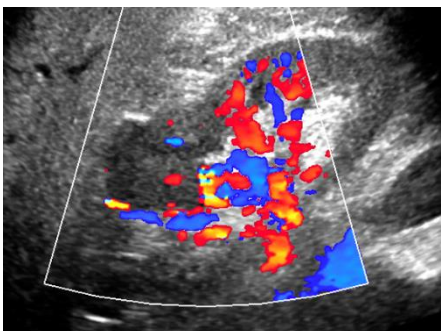


Nefrocalcinose cortical

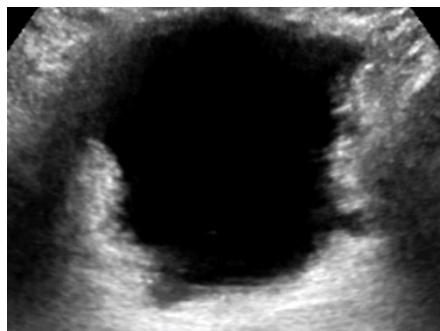


Rim transplantado

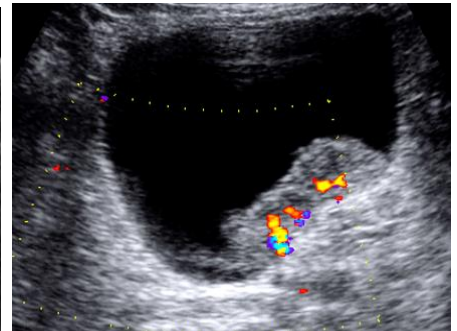
Disciplina 4. Ultrassonografia do Aparelho Urinário. Parte 6. Alguns exemplos:



Carcinoma renal



Bexiga de esforço

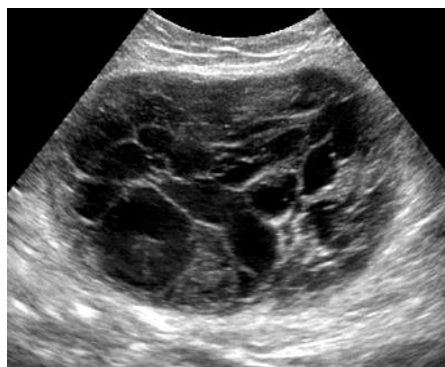


Carcinoma vesical

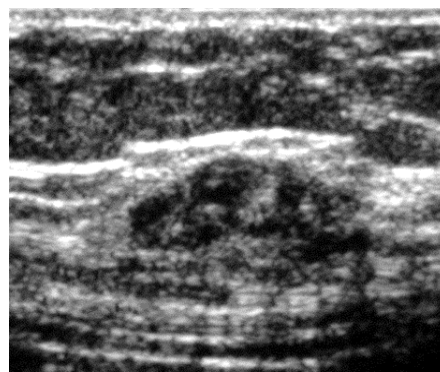
**Mês 22. Aulas Práticas.
80 pacientes agendados.**

Mês 23. Disciplinas:

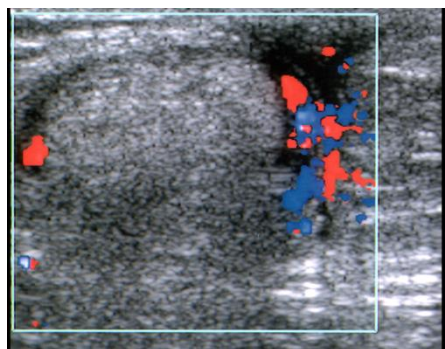
**Disciplina 1. A Iatrogenia em Tocoginecologia.
Alguns exemplos:**



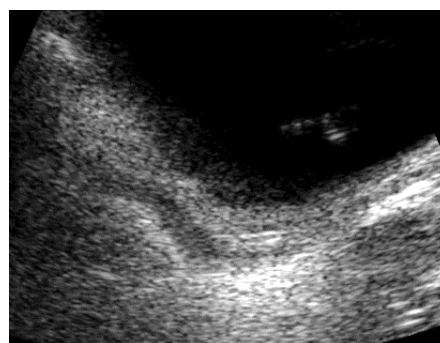
Hematoma



Granuloma

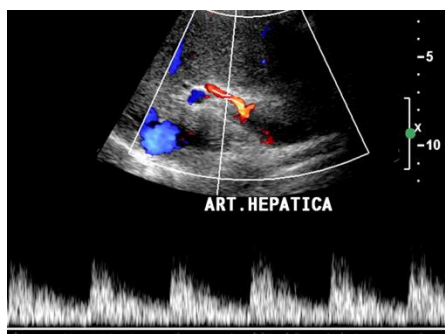


Hérnia incisional

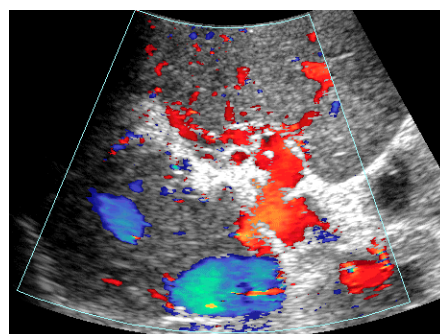


Trauma ureteral

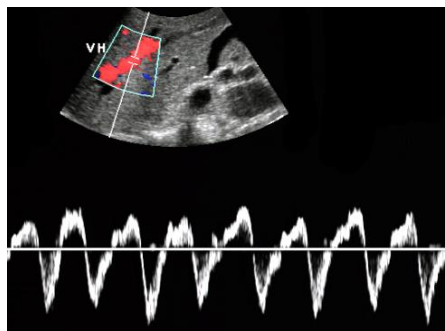
**Disciplina 2. Doppler Hepático.
Alguns exemplos:**



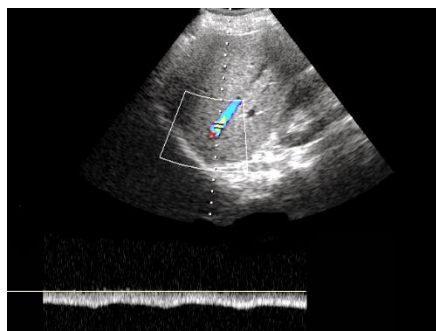
Artéria hepática



Cavernoma porta

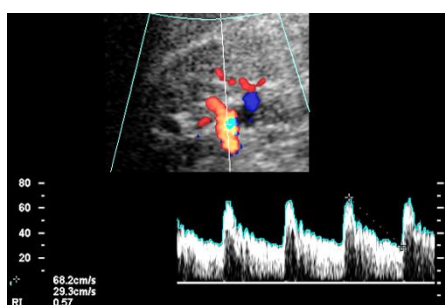


Insuficiência cardíaca

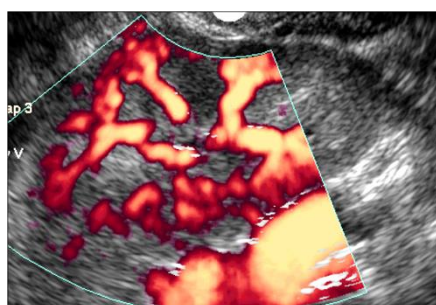


Fibrose hepática

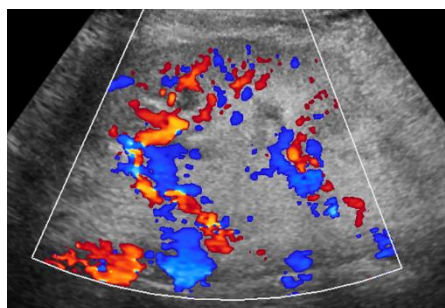
Disciplina 3. Doppler Renal.
Alguns exemplos:



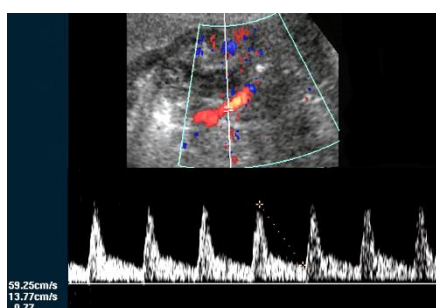
Artéria renal



Rim pélvico



Duplicação hilar



Pielonefrite crônica

Mês 24. Aulas Práticas.
80 pacientes agendados.

ENCERRAMENTO DO CURSO.